

Case Report: Management Penetrating Brain Injury Across Middle Third of Superior Sagittal Sinus

Achmad Chumaidi¹, Julius July²

¹ Neurosurgeon. Department of Neurosurgery, Sumber Waras Hospital. Cirebon, Indonesia

² Professor of Neurosurgery. Neurosurgery Department, Siloam Hospital Lippo Village - Karawaci, Indonesia

Abstract

Citation: Chumaidi Achmad, July Julius. Case Report: Management Penetrating Brain Injury Across Middle Third of Superior Sagittal Sinus. *Medicus*. 2022 February; 10(2):96-102
Keywords: Craniotomy; Machete; Penetrating brain injury; Superior sagittal sinus
Correspondance: Achmad Chumaidi. Department of Neurosurgery, Sumber Waras Hospital Jl. Urip Sumoharjo No 5, Ciwaringin, Kabupaten Cirebon. 45167 West Java
E-mail: ahmad_crg@yahoo.com
Online First : June 2022

Background: Penetrating cranial injuries are rarely reported on thick parietal bone. Goal of its management include removal of the foreign object while minimizing further damage to the brain and associated neurovascular structures, also prevent further complications.

Case Description: We report a case of a 22-year-old male presented with machete stucked in his head following an accidentally fell down of the weapon from a coconut tree. The cranial location affected were midparietal. He was disoriented on admission, with neither neurological focal signs nor seizure. Computed tomography (CT) revealed that the object penetrate middle superior sagittal sinus. After emergency craniotomy to remove the objects, debridement, dural sinus repair were performed. Recovery was complete without sequelae.

Conclusion: Laceration of the middle thirds of the superior sagittal sinus require special handling and care during surgery. Operative approach and treatment strategies are among the most important considerations to achieve the best patient outcomes.

Introduction

Penetrating brain injury (PBI) are relatively uncommon, representing about 0.4% of head trauma.^{1,2} It may caused by either low velocity sharp objects or high velocity projectiles.³ Morbidity and mortality following PBI remains high due to severe brain and vascular injury, also the secondary lesions from edema and sepsis that may occur.¹ We report a case in which a foreign body invaded middle third of superior sagittal sinus (SSS) through the midparietal bone.

Case Description

A 22-year-old male, a pedestrian who received on the head long sharp iron machete in free fall from a 15 metres tall coconut tree. He was admitted after 2 hours of injury, complained with severe headache. History of convulsion, and signs of meningitis were absent. At the emergency room, he was clinically drowsy, Glasgow Coma Scale 14/15, stable vital signs without focal neurologic deficit presenting a parietal medial wound of 5 cm crossed by a sharp piece of 70 cm long weapon. (Figure 1)

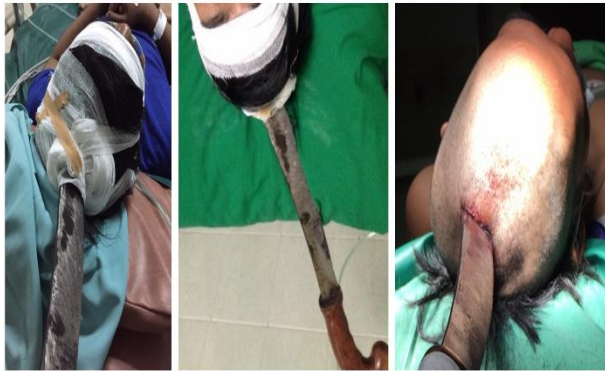

Figure 1. Macroscopic view of a penetrating craniocerebral injury caused by a machete, whose point of penetration is visible in the mid parietal region

Head computed tomography (CT) scan and 3D reconstruction was performed showing an open depressed skull fracture; with the weapon lodged in the mid parietal bone with a depth of approximately 6 to 7 cm. There was impression of both external and internal parietal bone tables and caused a slight subarachnoid hemorrhage. Because of the artifact, we could not determine the relationship between the objects and superior sagittal sinus (Figure 2).

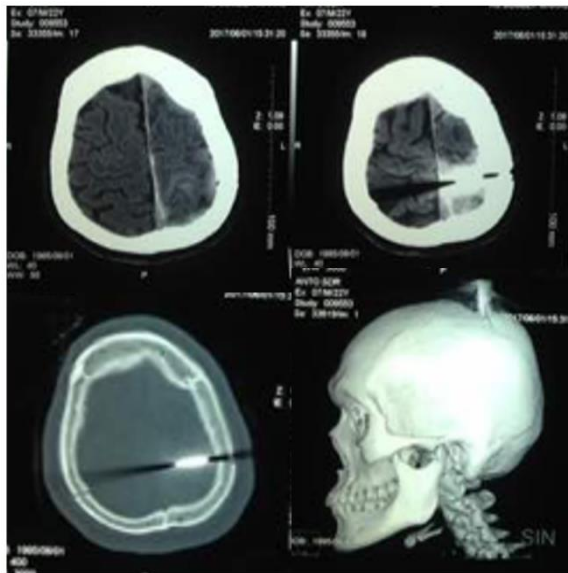


Figure 2. Computed tomography (CT) of the head and skull showed a hyperdense foreign body on the left side of the parietal region the associated presence of left cerebral contusion and subarachnoid hemorrhage

After blood transfusion preparation, antitetanus and prophylactic antibiotics, he underwent surgery under general anesthesia in supine position, slightly flexed neck. Surgical exploration was performed as follow: with a mid parietal horse shoe skin flap incision, the objects was removed along with a bone flap performed by 4 burr holes from each side of the superior sagittal sinus. A parasagittal craniectomy was done 3-4 cm around the objects, a fascia for dural graft was prepared. Dural cross opening with center at the site of the stab entry. Subsequently, we detected the penetrating point using a microscope

The objects was gently extracted keeping in line with its trajectory, removed by directly looking at its tip intracranially, followed by continuous irrigation to prevent air embolism. The dura was irregularly torn involving lateral wall of SSS with underlying 5 cm deep laceration of parietal cortex. The lateral sinus wall was gently pressured with cottonoid for few minutes and packed with absorbable hemostatic agent; Gelfoam (Pfizer, Brooklyn, New York, USA) and Surgicel fibrillar (Ethicon, Somerville, New Jersey, USA).

Subsequently, duraplasty using facial graft was performed to stop profuse bleeding. After careful hemostasis, the wound was inspected under direct vision for any bleeding, or cerebrospinal fluid flow. Bridging veins are preserved. The brain was thoroughly irrigated using normal saline and antibiotic. We excised bony fragments to prevent infection. The bone flap wasn't put back due to brain edema. Blood pressure, volume and viscosity were carefully monitored during and after surgery to assure sinus patency. Removed foreign body was cultured for aerobic, anaerobic, or fungal pathogens. All cultures were negative.

The patient improved post-operatively, he was awake, more coherent, ambulating without difficulty, no focal neurologic deficits, sign of infection and neither sign of raised intracranial pressure. He was managed with anti edema, analgesics, and anticonvulsants.

For antibiotics, we gave Ceftriaxone 4g/ day and Metronidazole 1500 g/ day. Patient was discharged on the 7th post-operative day without any sequelae (Figure 3).

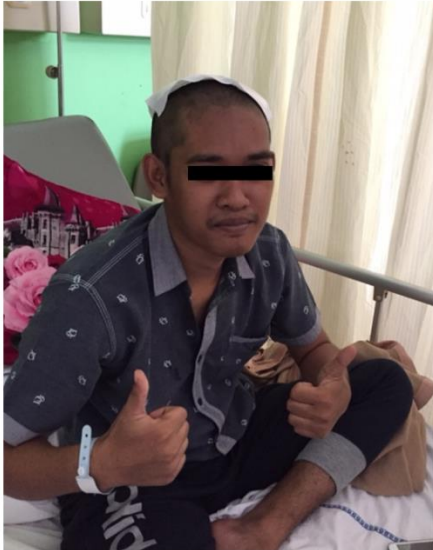

Figure 3. Post operative general condition

Discussion

PBI is defined as a lesion caused by an object that gets through the skull and the dura mater and remains inside, can result from a variety of objects, both low and high velocity objects which may cause significant damage to the brain resulting in severe neurological deficits. The traumatic dural venous sinus injury is one of the most dangerous complications of PBI, with its incidence to be raised to 4-12% of all brain trauma case, with a reported mortality rate of 41%.⁴

Usually, it occur on thin bones, especially the orbit and the squamous temporal bone. Parietal region is rarely traversed by a penetrating object as in our case.^{5,6,7} Sharp objects causing PBI is also relatively uncommon, most of them are accidental injuries. Elkatatny et al, reveals most common cause traumatic dural venous sinus injuries was heavy object (45 %), road traffic accident (25%) followed by fall from height injury (20%), and sharp objects (10%).⁸

Unusual PBI have been scattered reported to be caused by tree branches, sticks and fragments of wood, bamboo groove, nails, metal poles, ice picks, keys, pencils, chopsticks, and power drills.^{9,10,11} Increased vascular complications and mortality were noted in penetrating retained objects compared to those which did not, because it tend to be deeply penetrating with a potential for more cerebral and vascular injury.^{12,13}

According to its localization, most common site of dural sinuses injuries are superior sagittal sinus (75%), followed by transverse sinus (15%), sigmoid sinus (5%) and multiple sinus (5%). These injuries may be fatal due to the potential to cause prolonged disability or death, either due to profuse venous bleeding, venous hypertension, ischemia, hydrocephalus or increased intracranial pressure due to impaired cerebral venous drainage. Although rare, post traumatic dural sinus thrombosis may happen and lead to hemorrhagic infarction and fatal conditions.⁸

As preoperative study, it is necessary to evaluate not only head CT but also 3D reconstruction and angiography. Sinus injury should be suspected if preoperative CT shows hematoma overlying venous sinuses, or fractures which crossed the sinus. Due to lack facilities, we did not perform further angiographic evaluation prior to surgery.¹⁴

The surgical management depends on the extent of injury and structures involved. It is recommended to perform surgery within 12 hours after the injury to prevent infection.¹⁵ Our treatment was immediate and identical to that reported by other authors, consists of wound exploration, craniotomy/ craniectomy, debridement of devitalized brain tissue, evacuation of hematoma, careful extraction foreign body and retained fragments if possible, bleeding control, vascular repair, lavage of the wound and water tight dural closure.^{16,17} Continuous irrigation over the sinus during the elevation of the foreign body fragments are suggested to reduce the chance of embolism.

The use of broad spectrum antibiotics is recommended to prevent infectious complications.⁸

In our case, surgical removal of the foreign body from the bone may worsened SSS injury. In concordance with Fischer et al and Nussbaum et al, firstly, we tried to have a direct visualization through the puncture side. Skin flap and craniotomy should extend across the midline to permit visualisation of both sides of the sinus. Then parts of the bone were removed in order to remove the blade from the bone.^{18,19} Direct visualization of foreign object should be achieved before its removal. Thorough debridement and irrigation along the exposed trajectory has a great significance to prevent postoperative infection and CSF leakage.^{20,21}

Bleeding occurred due to sinus wall laceration during removal the tip of the machete. Various operative technique for sinus injury treatment including direct compression by gelfoam, stitching the dura up to adjacent bone, direct stitching of dural tear, and muscle duraplasty. During direct compression of the sinus, further complication should be considered. Sinus occlusion / thrombosis may occur following free muscle duroplasty or coagulation system activation due to damage endothelial lining of the sinus wall.⁸ If there was total destruction of the sinus causing uncontrollable haemorrhage, however, ligation of the middle and posterior thirds might be considered, since it is not necessarily associated with a poor prognosis.²²

Cerebral infections or meningitis are fatal complications.²⁰ Infection is the main complication of PBI with a reported overall rate of 64–70% and mortality rate of 14–57%. In previous publications, prophylactic use of broad-spectrum antibiotic was suggested within 7–14 days after the injury,^{22,23} while others indicated that antibiotic therapy should be administered according to the findings of cerebrospinal fluid culture.²⁰ Intravenous antibiotics, laboratory examination and closed observation of any sign of infection are

mandatory during post operative hospitalization.

Approximately 30%-% of patients with penetrating brain injury develop seizures. Between 4% and 10% have their first seizure within the first week of injury, and 80% of patients have a seizure during the first 2 years.^{22,24} Antiepileptic medication has been shown to prevent the occurrence of early seizures. For this reason, prophylaxis is recommended for the first 7 days after injury.²³ Our patient had antiepileptic medication during hospitalization due to brain tissue damage and edema that had raised increased concern for risk of posttraumatic seizures.

During hospitalization, any sign of increased intracranial pressure should be taken into consideration. Post operative imaging follow up including non-contrast Head CT to assess hemorrhage, or venous infarction in the form of petechial hyperdensity and hypodense edema which may be seen in the cortical grey matter and sub cortical white matter due to sinus obstruction. Follow up MRV should be a good definitive diagnostic tool for those suspected cases.⁸ Early detection and early management with anticoagulation of this potentially treatable condition will result in good outcome. In our case the patient was not showed any sign of raised ICP, we did not perform any post operative angiographic imaging studies, and the patient was not placed into anticoagulant therapy due to risk of postoperative bleeding

Conclusion

Penetrating brain injury with superior sagittal sinus tear is uncommon. It can pose unique difficulties and lifethreatening conditions. Therefore, it require rapid intensive resuscitation, comprehensive pre and post operative imaging study and careful individualized neurosurgical treatment. Further complication during recovery period should always be taken into consideration.

References

1. Zhang D, Chen J, Han K, Yu M, Hou L. Management of Penetrating Skull Base Injury: A Single institutional experience and review of the literature. *BioMed Research International*. 2017;28(3):1-12. <https://doi.org/10.1155%2F2017%2F2838167>
2. Wu R, Ye Y, Liu C, Yang C, Qin H. Management of penetrating brain injury caused by a nail gun: three case reports and literature review. *World Neurosurg*. 2018;112:143-7. <https://doi.org/10.1016/j.wneu.2018.01.127>
3. Tablada H, Pena D, Mustelier M, Cruz N Fuentes H. Herida penetrante del cráneo (síndrome de Jael) por arma blanca. *Revista Cubana de Neurología y Neurocirugía*. 2020;10(1):e359.
4. Meier U, Gärtner F, Knopf W, Klötzer R, Wolf O. The traumatic dural sinus injury-a clinical study. *Acta neurochirurgica*. 1992; 119(1-4):91-3. <https://doi.org/10.1007/bf01541788>
5. Sösüncü E, Hakan AK, Gülşen I, Akyüz Y, Arslan M. Concealed penetrating parietal lobe injury due to stab wound: Case report. *Austin J Emerg Crit Care Med* 2014;1(1):2.
6. Yarandi KK, Jelodar S, Khalatbari MR, Rasras S, Ilkhchi RB, Amirjamshidi A. Stab wounds to the head; case series, review of literature, and proposed management algorithm. *Asian J Neurosurg* 2018;13:754-9. https://doi.org/10.4103/ajns.AJNS_29_18
7. Srivastava C, Singh SK, Ojha BK, ChandraA. Intracranial penetrating glass injury: A case report. *Indian J Neurotrauma* 2012;9:64-6. <http://dx.doi.org/10.1016/j.ijnt.2012.04.003>
8. Elkatatny AAAM, Elreheem YAA, Hamdy T. Traumatic Dural Venous Injury. *Open Access Maced J Med Sci*. 2019 Oct 15; 7(19):3225-3234. <https://doi.org/10.3889/oamjms.2019.535>
9. Pascual JM, Navas M, Carrasco R. Penetrating ballistic-like frontal brain injury caused by a metallic rod. *Acta Neurochir* 2009;151:689–91. <https://doi.org/10.1007/s00701-009-0222-8>
10. Salar G, Costella GB, Mottaran R, Mattana M, Gazzola L, Munari M. Multiple craniocerebral injuries from penetrating nails. Case illustration. *J Neurosurg*. 2004;100:963.
11. Bakay L, Glasauer FE, Grand W. Unusual intracranial foreign bodies. Report of five cases. *Acta Neurochir (Wien)* 1977;39:219–31. <https://doi.org/10.3171/jns.2004.100.5.0963>
12. Taylor AG, Peter JC. Patients with retained transcranial knife blades: A high-risk group. *J Neurosurg*. 1997;87:512–5. <https://doi.org/10.3171/jns.1997.87.4.0512>
13. Huo S, Cui F, Ohno Y. Fatal penetrating head injury by bamboo fragments. *Legal Medicine* 15 (2013) 99–102. <https://doi.org/10.1016/j.legalmed.2012.08.013>
14. Guidelines for the Management of Penetrating Brain Injury. Neuroimaging in the management of penetrating brain injury. *J Trauma* 2001;51:S7-11.

15. Miki K, Natori Y, Kai Y, Mori M, Yamada T, Noguchi N. How to Remove a Penetrating Intracranial Nail. *World Neurosurg.* (2019) 127:442-445. <https://doi.org/10.1016/j.wneu.2019.04.161>
16. Fatigba, O.H., Hodé, L. and Padonou, C. (2020) Intentional Penetrating Craniocerebral Injury Caused by a Nail: Clinical Presentation and Management of Three Cases. *Open Journal of Modern Neurosurgery* 2020; 10: 458-463. <https://doi.org/10.4236/ojmn.2020.104046>
17. Jeon YH, Kim DM, Kim SH, Kim SW. Serious penetrating craniocerebral injury caused by a nail gun. *J of Korean Neurosurgical Society* 2014;56:537-9. <https://doi.org/10.3340/jkns.2014.56.6.537>
18. Fischer BR, Yasin Y, Holling M, et al. Good clinical practice in dubious head trauma - the problem of retained intracranial foreign bodies. *Int J Gen Med* 2012;5:899–902. <https://doi.org/10.2147/ijgm.s35925>
19. Nussbaum ES, Graupman P, Patel PD. Repair of the superior sagittal sinus following penetrating intracranial injury caused by nail gun accident: case report and technical note. *British Journal of Neurosurgery.* 2019; 20:1-5. <https://doi.org/10.1080/02688697.2019.1630550>
20. Zhang D, Chen J, Han K, Yu M, Hou L. Management of Penetrating Skull Base Injury: A Single Institutional Experience and Review of the Literature. *Hindawi BioMed Research International.* 2017. <https://doi.org/10.1155/2017/2838167>
21. Ferraz VR, Aguiar GB, Vitorino-Araujo JL, Badke GL, Veig JCE. Management of a Low-Energy Penetrating Brain Injury Caused by a Nail. *Hindawi Publishing Corporation.* 2016. <https://doi.org/10.1155/2016/4371367>
22. Ramos R, Antunes C, Machado MJ, et al. Penetrating head trauma injury with an excellent outcome. *British Medical Journal* 2017-219746. <https://doi.org/10.1136%2Fbcr-2017-219746>
23. Williams JR, Aghion DM, Doberstein CE, Cosgrove RG, Asaad WF. Penetrating brain injury after suicide attempt with speargun: case study and review of literature. *Frontiers in Neurology*, 2014;5:1-13. <https://doi.org/10.3389%2Ffneur.2014.00113>
24. Zyck S, Toshkezi G, Krishnamurthy S, Carter DA, Siddiqui A, Hazama A. Treatment of Penetrating Nonmissile Traumatic Brain Injury. *World Neurosurg.* 2016; 91:297-307. <https://doi.org/10.1016/j.wneu.2016.04.012>
25. Hengzhu Z, Enxi X, Lei S, Xiaodong W, Lun D. A rare case of penetrating brain injury by crossbow in a 22-month old child. *Pediatr Emerg Care.* 2014;30:421-423. <https://doi.org/10.1097/pec.000000000000153>

Author's Statement

The authors declared that all the images and figures in this manuscript is/are author's own work and/or has obtained necessary permission to re-use the content from the authors and publisher of respective materials.

A handwritten signature in black ink, appearing to read 'Achmad Chumaidi', with a stylized flourish at the end.

Achmad Chumaidi