

The Role of Bone Scintigraphy and Parathyroid Scintigraphy on Multiple Osteolytic Lesions Which Misdiagnosed as Primary Bone Tumor (Giant Cell Tumor)

Nora A. Prasetyo¹, Budi Darmawan², Erwin Affandi³, A. Hussein S. Kartamihardja⁴

^{1,2,3,4} *Department of Nuclear Medicine and Theranostic Molecular Dr. Hasan Sadikin*

^{1,2,3,4} *General Hospital Bandung - Faculty of Medicine Universitas Padjadjaran Bandung*

Abstract

Citation: Prasetyo Nora A., Darmawan Budi, Affandi Erwin, S. Kartamihardja A. Hussein. The Role of Bone Scintigraphy and Parathyroid Scintigraphy on Multiple Osteolytic Lesions Which Misdiagnosed as Primary Bone Tumor (Giant Cell Tumor). *Medicus*. 2022 February; 10(1):42-49

Keywords: Bone scintigraphy; Parathyroid scintigraphy; Multiple osteolytic lesions; Primary bone tumor; Giant cell tumor

Correspondance: Nora A. Prasetyo. Department of Nuclear Medicine and Theranostic Molecular Dr. Hasan Sadikin

E-mail: noraprasetyo2004@gmail.com

Online First : March 2022

Brown tumor is a non-neoplastic lesion that resulting from abnormal bone metabolism. It can be manifest in prolonged or untreated hyperparathyroidism. The clinical symptoms, radiological and histopathological examination were similar with giant cell tumor and can be mimicking metastases; or even misdiagnosed with giant cell tumor and mistreated the patient. Biochemical examination of calcium levels and parathyroid hormone should be included in the routine assessment of patients with multiple osteolytic lesions. A multidiscipline approach is needed. Throughout this case report, we would like to report the important role of Nuclear Medicine and Molecular Theranostic imaging modality in 38-year-old male with multiple osteolytic lesions, which was first diagnosed as giant cell tumor and differential diagnosis bone metastases but turnout to be a metabolic bone disease (brown tumor) with parathyroid adenoma as etiology.

Introduction

Primary bone tumors could be manifest as malignant or benign tumor. One of benign primary bone tumor is giant cell tumor.¹ Brown tumor is one of the differential diagnoses of giant cell tumor. It is a metabolic bone disease which could be found in hyperparathyroidism patients. Further imaging often requested by clinician to evaluate patient's condition thoroughly especially when multiple osteolytic bone lesions were found because giant cell tumor and brown tumor show similar clinical symptoms, radiologic, and histopathologic finding but the management is very different.^{2,3}

European Society of Musculoskeletal Radiology (ESSR) declare that imaging modalities has a very important role to diagnosis bone tumors. Imaging modalities have two

complementary types: morphological that depends mainly on structural changes and functional modalities that depend on the physiological changes.⁴

Throughout this case report, we would like to report the role of imaging modality in nuclear medicine as functional modality in 38-year-old male with multiple osteolytic lesions, which was first diagnosed as giant cell tumor and differential diagnosis bone metastases but turnout to be a metabolic bone disease (brown tumor) with parathyroid adenoma as etiology.

Case illustration

Mr. WS, a 38-year-old male, was referred to Department of Nuclear Medicine and Theranostic Molecular Dr.

Hasan Sadikin General Hospital Bandung to undergo bone scintigraphy. He was referred with thoracal myeloradiculopathy (Th-VIII) and primary bone tumor as working diagnosis with metastasis and osteosarcoma as differential diagnosis.

He came with pain and swelling of all extremities, especially upper right extremity, as main complaint. These were preceded by intermittent pain for 2 years ago. Initially, pain was felt on right leg for 3 months, and then it was felt moving between all of the extremities. Movement of the extremities was limited by these pain sensations. Right upper extremity started to get swollen 10 months ago, whereas the left leg started 3 months ago. There were no radiating pain and numb sensation felt. There was 10 kg weight reduction in 3 months. History of broken left shoulder due to trauma 10 years ago. Patient said that there was stone when he urinated and sometimes it was mixed with blood in the last 3 years.

Vital sign and generalized status of the patients were within normal limit. Deformity and hard mass were found on middle of left forearm, proximal of upper right arm, and proximal to middle of left leg (Figure 1).

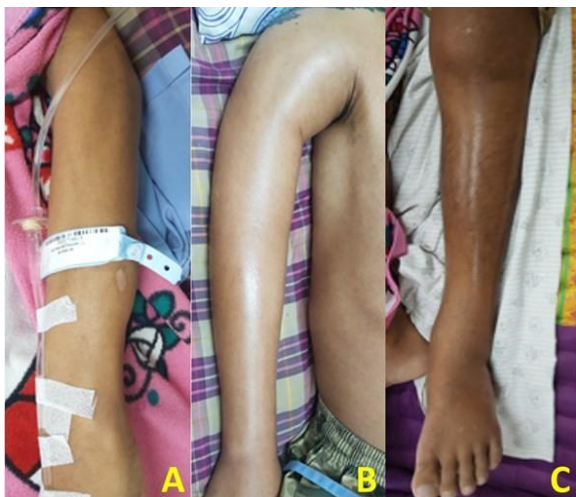


Figure 1. Deformity and hard mass on middle proximal of left forearm (A), proximal of upper right arm (B), and proximal to middle of left leg (C).

Bone biopsy from proximal right humerus showed a result of giant cell tumor. Biochemical evaluation showed a result high level of calcium ion 6.54 mg/dL (Normal range: 4.5 – 5.6 mg/dL) with normal kidney function. The radiographic imaging X-ray result of right shoulder and left forearm showed as a soft tissue mass with multiple lytic lesion which destruct the diaphysis-metaphysis-epiphysis of proximal humerus, scapula, and diaphysis of ulna (Figure 2).

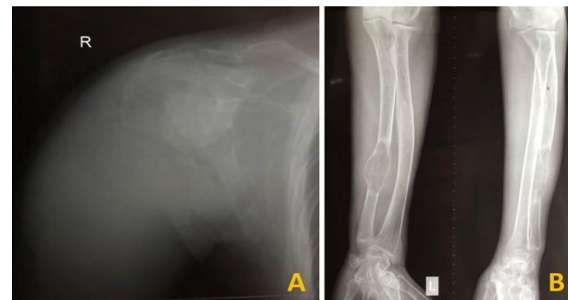

Figure 2. The radiographic imaging of right shoulder (A) and left forearm (B)

Patient was referred to our Nuclear Medicine and Molecular Theranostic Department to perform bone scintigraphy. From bone scintigraphy (Figure 3) we found a diffuse increase of radioactivity uptake on the skull. There was also an inhomogeneous radiopharmaceutical uptake on both humerus, right antebrachial, left iliac crest, distal right femur, and both proximal of tibia. It also showed multiple hotspots on left clavicle, both anterior of costae-I, anterior of right costae-V and left costae-VI, posterior of left costae-IX and XI, left antebrachial, both metacarpals and phalanges, left metatarsal, both ischia, both the head of femur, also both sacroiliac joints. Retention of radiopharmaceutical was seen in right kidney and left kidney was not visualized. These patterns of radioactivity uptake are characteristics of metabolic bone disease with obstruction process of the right kidney.

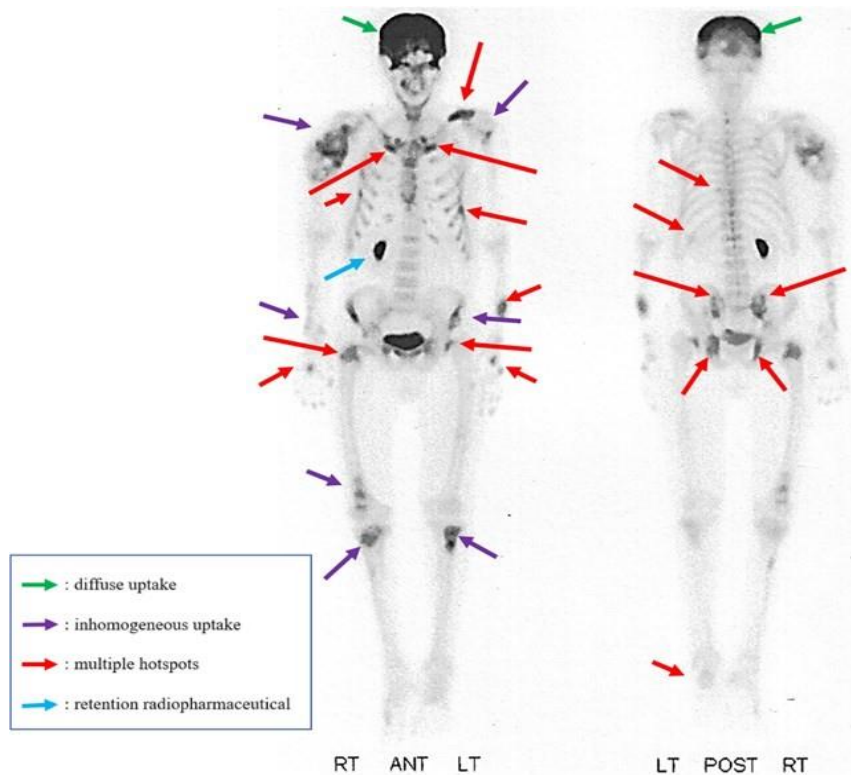


Figure 3. Bone scintigraphy findings

Afterward, patient was suggested to undergo another biochemical evaluation and it showed a high level of parathyroid hormone (PTH) 1,147 pg/mL (Normal range: 15-65 pg/mL), and low level of total vitamin D-25-OH 2.3 ng/mL (Normal range: 30-100 ng/mL).

And then, parathyroid scintigraphy was performed (Figure 4). It showed a pathologic radioactivity uptake on single hyperfunction parathyroid gland at inferior and posterior aspect of right thyroid lobe. It was concluded as a parathyroid adenoma located at inferior and posterior aspect of right thyroid lobe.

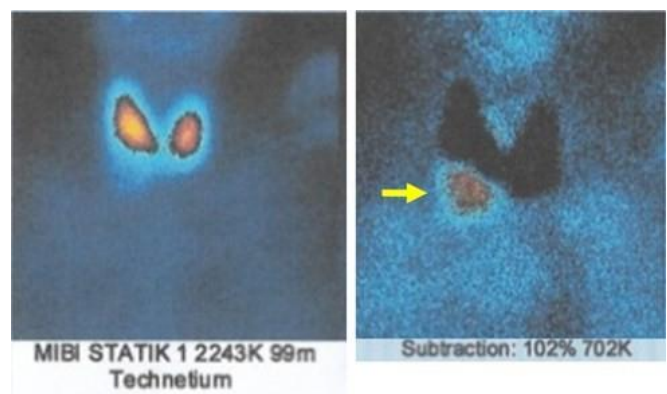


Figure 4. Parathyroid scintigraphy

Patient directly underwent parathyroidectomy procedure after the diagnosis of parathyroid adenoma has been made. Surgeon found the parathyroid adenoma at inferior and posterior aspect of right thyroid lobe, as seen on parathyroid scintigraphy. Histopathology report showed parathyroid adenoma. Patient's condition is improving after parathyroidectomy was done, and patient undergo therapy for hypocalcemia.

Case Discussion

Brown tumor is a non-neoplastic lesion that resulting from abnormal bone metabolism (imbalance of osteoclast and osteoblast activity that bone resorption exceeding bone formation) such in hyperparathyroidism case. It can be manifest in prolonged or untreated hyperparathyroidism (primary, secondary, or tertiary). There is female predominance compare to males, and the incidence increases with age (most cases reported in more than 50 years old and greater in post-menopausal women). The clinical symptoms can be asymptomatic swelling or with bone pain, pathologic fracture, hypercalcemia (renal stones). From radiological examination show osteolytic lesions mimicking metastases; their differential diagnosis includes primary bone metastasis, chondroma, aneurysmal bone cyst, osteosarcoma, and giant cell tumor. Diagnostic dilemma arises when multiple osteolytic lesions appear at different area of the skeletal, as in our case report. Because brown tumor and giant cell tumor have similar clinical, radiological, and histopathological finding, we need including brown tumor as differential diagnosis of multiple osteolytic bone lesions, in order to avoid unnecessary and harmful surgical interventions. Biochemical examination of calcium levels, and parathyroid hormone should be included in the routine assessment of patients with multiple osteolytic lesions. A multidiscipline approach is needed.^{5,6}

Primary bone tumor could manifest as malignant or benign lesions. Several benign bone tumor could show high intensity radiopharmaceutical uptake, thus malignancy has to be ruled out. One of the benign tumor with such characteristic is giant cell tumor.¹ Giant cell tumor is originated from fibrous tissue of bone marrow. It emerged between the age of 10-70 years old (most frequently between 20-40 years old) with tendency towards female. The most frequent affected region would be metaphysis-epiphysis part of the long bone. Giant cell tumor mainly will emerge on knee (50%), radius, and humerus. It has high recurrency rate and often affecting surrounding tissue. The tumor consist of giant cell, which resemble osteoclast and anaplastic stromal cell, with a little bit of osteoid and collagen component.⁷ One of the differential diagnosis of giant cell tumor is brown tumor, which is often found on hyperparathyroidism patients. Giant cell tumor and brown tumor have similar histopathology, thus imaging is should be requested by clinician, especially when multiple osteolytic lesions were found.^{2,3}

In present case report, 38-years-old male with history of multiple bone mass and sensation of pain with movement. There were multiple osteolytic lesions on the long bones (diaphysis-metaphysis-epiphysis of proximal humerus and diaphysis of ulna) on radiographic imaging X-ray. Thus, bone biopsy was performed on right humerus, and the result was giant cell tumor. Because of multiple osteolytic lesions and giant cell tumor resembling a malignancy condition, the clinician reffered the patient to undergo whole body bone scintigraphy to find out whether there were another osteolytic lesions.

Bone consists of protein and mineral with mainly composed of collagen, calcium, and pyrophosphate. Around 5 – 10% of the bone undergo regeneration during young adult period. Most of the calcium (99%) which are contained in the bone are in the form of hydroxyapatite. Later, the bone will be stabilized in adult

skeleton, and actively maintaining the equilibrium through modeling and remodeling process. These processes require the serum calcium homeostasis. In condition where the disease disrupt the calcium homeostasis, clinical symptoms of metabolic bone disease manifest.⁸

Metabolic bone disease (MBD) is a group of clinical manifestation which leads to the mineralization impairment, mass, and the deformity of the bone. It is often characterized by extreme bone abnormalities which will improve after treatment according to the etiology. Bone mineral equilibrium is influenced by several minerals, including calcium, phosphor, magnesium, and vitamin D. Although metabolic bone disease are common, it is difficult to diagnose based on clinical condition and conventional radiological modality.^{8,9} Some of the disease that can cause metabolic bone disease are renal osteodystrophy, hyperparathyroidism, and vitamin D deficiency in osteomalacia and Paget's disease.¹ One of the causes of MBD is the over excretion of parathyroid hormone (PTH) which trigger bone resorption process thus resulting in hypercalcemia and hypophosphatemia.⁹ This was first discovered by Friedrich Schlaugenhauer in 1915. Blood examination is usually performed to screen hypercalcemia. MBD could be evaluated by bone scintigraphy.⁷

European Society of Musculoskeletal Radiology (ESSR) declare that imaging modalities has a very important role to diagnosis bone tumors. Imaging modalities have two complementary types, either morphological that depends mainly on structural changes (radiographic, ultrasonography, computed tomography (CT), and magnetic resonance imaging (MRI)) or functional modalities that depend on the physiological changes (bone scintigraphy). Radiographic imaging assessment is needed to check the pattern of bone destruction, zone of transition, periosteal reaction, cortical destruction, soft tissue / joint involvement, and the location of the bone tumor

(predilection). Bone scintigraphy is useful for local / distant staging of bone tumors, and in case of primary bone tumor, bone scintigraphy could help in diagnosis because has specific features as we seen in this present case.^{4,10}

Bone scintigraphy is one of the imaging modalities in nuclear medicine. Radiopharmaceutical, ^{99m}Tc-methylene diphosphonate (^{99m}Tc-MDP), will be injected intravenously 3 hours before a whole-body scan is performed. Radiopharmaceutical ^{99m}Tc-MDP will bind to crystalline hydroxyapatite and amorphous calcium phosphate thus resulting uptake of radioactivity at the site of mineralized bone. Several factors that influence radioactivity uptake by ^{99m}Tc-MDP are blood flow, vitamin D level, parathyroid hormone level, corticosteroid, intraosseous tissue pressure, and blood vessel permeability.¹⁰

In the early stages of metabolic MBD, bone scintigraphy shows diffuse radioactivity uptake. In line with the disease progressivity, bone scintigraphy has well recognized features, such as a focal radioactivity uptake in bones with high bone turnover (fractures or pseudofractures) and brown tumor. It will also show "superscan" pattern (increase bone and soft tissue uptake ratio, faint or absent radioactivity uptake in the kidney) - a classic characteristic of MBD on bone scintigraphy- and higher radioactivity uptake on the axial bones as well as proximal part of the long bones. Diffuse radioactivity uptake on the periarticular areas, calvaria, mandible, sternum, and costochondral junction also classical bone scintigraphy finding in MBD.^{1,9}

This patient underwent bone scintigraphy and it showed a diffuse increase radioactivity uptake on calvaria, inhomogeneous radioactivity uptake on long bones (both humerus, both antibrachial, both metacarpals and phalanges, both femurs, both the proximal of tibia, left metatarsal), and multiple hotspots on the surrounding area of the joint (both the head of femur, both

sacroiliac joints). It also showed “superscan” pattern - left kidney was not visualized (the retention of radiopharmaceutical in right kidney can be cause by kidney stone). This increase uptake on a whole-body bone scintigraphy, the elevated serum calcium, patient’s history of stone excretion in urine were the clues that pointed our attention toward metabolic bone disease (brown tumor) with hyperparathyroidism as suspected aetiology in this patient. As biochemical examination showed a high level of parathyroid hormone and low level vitamin D with normal kidney function, we conclude the high possibility of adenoma parathyroid in this patient.

Primary, secondary, and tertiary hyperparathyroidism will cause the increase of calcium and parathyroid hormone. All type of hyperparathyroidism will increase the bone resorption process thus increasing osteoblastic activity that cause increasing radioactivity uptake of MDP.⁹ Parathyroid adenoma is the main cause of primary hyperparathyroidism (in 80% of all cases). Parathyroidectomy show high success rate in primary hyperparathyroidism management, thus an imaging modality to localize the affected parathyroid gland is necessary to be performed to reduce the morbidity of the parathyroidectomy procedure.^{6,7}

Several traditional non-invasive modalities, such as computed tomography (CT), ultrasonography (USG), and magnetic resonance imaging (MRI), not been considered very useful for preoperative localization because could not determine the hyperfunctioning parathyroid gland or the surrounding tissue. The most sensitive, cost-effective, and non-invasive modality in determining the hyperfunctioning parathyroid gland is parathyroid scintigraphy ($\pm 80-100\%$ vs $46-76\%$ (CT) vs $36-76\%$ (USG) vs $50-78\%$ (MRI)).⁷ Parathyroid scintigraphy could show false negative as well as false positive result. The hyperfunctioning parathyroid gland that are too small and multiple parathyroid adenomas could cause a false negative result. Whereas

follicular thyroid adenoma, thyroid cancer, benign neoplasm, and metastasis could cause false positive result. Consumption of calcium channel blocker could activate the p-glycoprotein which could increase the washout of the radiopharmaceutical, thus leading to false negative result.¹¹

Parathyroid scintigraphy using ^{99m}Tc- Sestamibi subtraction method was done on this patient, and it showed a single hyperfunction parathyroid gland at inferior and posterior aspect of right thyroid lobe. This patient directly underwent parathyroidectomy procedure after the diagnosis of parathyroid adenoma has been made, and the location of hyperfunctioning parathyroid gland has been determined. Histopathology result after the parathyroidectomy procedure showed that it was indeed parathyroid adenoma.

In case of primary and secondary hyperparathyroidism, after parathyroidectomy usually hypocalcemia occurs temporarily, and the function of parathyroid gland will be normal in 1 week. However, persistent, and heavy hypocalcemia could be occurred in several cases even though parathyroid hormone has returned to normal.⁹ After parathyroidectomy procedure, the patient’s condition is improving, and patient undergo therapy for hypocalcemia.

Gosavi, et al. introduced an algorithm for diagnosis and treatment of primary hyperparathyroidism and exclusion of other giant cell lesions. Patient with asymptomatic or bone pain with osteolytic lesions on radiograph and giant cell in histopathology, should do a biochemical investigation such as parathyroid hormone and serum calcium, and perform parathyroid scintigraphy to localized the pathologic parathyroid gland prior surgery.⁶ If needed, a whole body bone scintigraphy could be use to look for other skeletal lesions.⁴

Conclusion

In case of multiple osteolytic lesions, history taking, clinical evaluation, imaging modality, histopathological examination, and biochemical investigation are useful to find the etiology. The nuclear medicine imaging modalities, such as bone scintigraphy -to find specific features of the radiopharmaceutical uptake- and parathyroid scintigraphy -the most sensitive, cost-effective, and non-invasive modality in determining the hyperfunctioning parathyroid gland- are useful and have an important role in

cases of multiple osteolytic lesions with hyperparathyroidism as its etiology. Brown tumor and giant cell tumor have similar clinical, radiological and histopathological findings. Therefore, it is important to provide the pathologist with all the appropriate laboratory and clinical data, not only the bone specimens. Biochemical investigation that is useful on all patients with bone tumors are serum calcium and parathyroid hormone. This could help to identify tumor such as brown tumors.

Acknowledgement

-

References

1. O'Malley JP, Ziessman HA. The Skeletal System. Dalam: Thrall JH, editor. Nuclear Medicine and Molecular Imaging: The Requisites. 5th ed. Philadelphia: Elsevier; 2021; 75-124.
2. Ghostine B, Sebaaly A, Ghanem I. Multifocal metachronous giant cell tumor: case report and review of the literature. *Case Rep Med*. 2014;2014:678035. <https://doi.org/10.1155/2014/678035>
3. Morey V, Sankineani SR, Kumar R. Multifocal metachronous giant cell tumour in bilateral upper limb: a rare case presentation. *Musculoskelet Surg*. 2014;98(2):165-9. <https://doi.org/10.1007/s12306-012-0223-2>
4. Lalam R, Bloem JL, Noebauer-Huhmann IM, Wortler K, Tagliafico A, Vanhoenacker F, et al. ESSR Consensus Document for Detection, Characterization, and Referral Pathway for Tumors and Tumorlike Lesions of Bone. *Semin Musculoskelet Radiol*. 2017;21(5):630-47. <https://doi.org/10.1055/s-0037-1606130>
5. Panagopoulos A, Tatani I, Kourea HP, Kokkalis ZT, Panagopoulos K, Megas P. Osteolytic lesions (brown tumors) of primary hyperparathyroidism misdiagnosed as multifocal giant cell tumor of the distal ulna and radius: a case report. *J Med Case Rep*. 2018;12(1):176. <https://doi.org/10.1186/s13256-018-1723-y>
6. Gosavi S, Kaur H, Gandhi P. Multifocal osteolytic lesions of jaw as a road map to diagnosis of brown tumor of hyperparathyroidism: A rare case report with review of literature. *J Oral Maxillofac Pathol*. 2020;24(Suppl 1):S59-S66. https://doi.org/10.4103/jomfp.JOMFP_319_19
7. Elgazzar AH. Parathyroid Gland. Dalam: Elgazzar AH, editor. The Pathophysiologic Basis of Nuclear Medicine. 2nd ed. Verlag-Berlin Heidelberg: Springer; 2006; 222-37. https://doi.org/10.1007/978-3-540-47953-6_8
8. El Demellawy D, Davila J, Shaw A, Nasr Y. Brief Review on Metabolic Bone Disease. *Acad Forensic Pathol*. 2018;8(3):611-40. <https://doi.org/10.1177/1925362118797737>

9. Elgazzar AH. Diagnosis of Metabolic, Endocrine, and Congenital Bone Disease. Dalam: Elgazzar AH, editor. Orthopedic Nuclear Medicine;10.1007/978-3-319-56167-7. 2nd ed. Switzerland: Springer 2017; 101-45. https://doi.org/10.1007/978-3-319-56167-7_3
10. Elgazzar AH. Basic Sciences of Bone and Joint Diseases. Dalam: Elgazzar AH, editor. Orthopedic Nuclear Medicine;10.1007/978-3-319-56167-7. 2th ed. Verlag Berlin Heidelberg:Springer; 2017; 1-36. https://doi.org/10.1007/978-3-319-56167-7_1
11. O'Malley JP, Ziessman HA. Endocrine System. Dalam: Thrall JH, editor. Nuclear Medicine and Molecular Imaging: The Requisites 5th ed. Philadelphia: Elsevier; 2021;152-79.

The authors declared that all the images and figures in this manuscript are author's own work and patient has given his consent for this case report to be written.

Signature,



Nora Anggun Prasetyo