

# Functional Endoscopic Orbital Decompression Surgery in Acute Rhinosinusitis with Orbital Complication : A Case Report

Michael Lekatompessy <sup>1</sup>, Amanda P Kirana <sup>1</sup>

<sup>1</sup> *Medicine Faculty of Pelita Harapan University*

## Abstract

**Introduction :** Orbital complication secondary to acute rhinosinusitis can cause permanent vision loss and death if not treated promptly and appropriately. The prevalence of orbital complications due to rhinosinusitis is more common in children than adults, occurring in 3-4% of children with acute rhinosinusitis. Lamina papyracea in children has many dehiscences, the nasal cavity tends to be narrower and the mucosa is softer than in adults, therefore causing the spread of infection more easily from the sinuses to the eyes. Clinical presentation : a 4 year old child presented with eye swelling and pus discharge in the right eye since 5 days before admitted to the hospital, for which she was treated with medication and did not improve. On physical examination, there is a narrow nasal cavity, inferior turbinate edema and hyperemia, mucopurulent discharge. CT scan and MRI revealed contrast enhancement in intraorbital with suspected intraorbital abscess with orbital cellulitis, right pansinusitis and buccal abscess. Functional endoscopic orbital decompression was done immediately.

**Conclusion :** Orbital complication due to acute rhinosinusitis are uncommon but potentially lead to more fatal complications. Early diagnosis and aggressive treatment of immediate functional endoscopic sinus surgery and antimicrobial therapy have good outcome.

**Citation :** Michael Lekatompessy, Amanda P Kirana. Functional Endoscopic Orbital Decompression Surgery in Acute Rhinosinusitis with Orbital Complication : A Case Report. *Medicinus*. 2021 February; 9(1):33-37  
**Keywords:** -  
**\*Correspondance :** Michael Lekatompessy, Medicine Faculty of Pelita Harapan University.  
**E-mail :** michael.lekatompessy @uph.edu  
**Online First :** September 2021

## Background

Orbital complication secondary to acute rhinosinusitis can cause permanent vision loss and death if not treated promptly and appropriately. Symptoms that indicate possible intraorbital complications are difficult to open the eyes due to edema, ophthalmoplegia, proptosis, decreased vision, and chemosis. More than 90% cases of orbital abscesses occur secondary to acute or chronic rhinosinusitis, with maxillary and ethmoid sinuses being the most common sources of infection. Other causes include ocular trauma, dacryocystitis, foreign bodies, dental infections (odontogenic), orbital tumors or intraocular tumors, and endophthalmitis.<sup>1</sup>

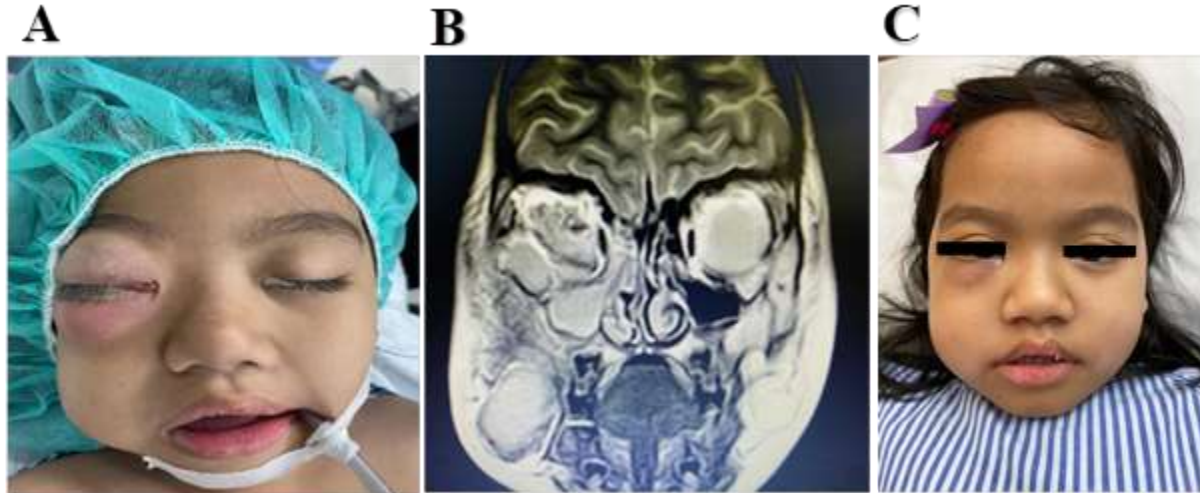
The prevalence of orbital complications

due to rhinosinusitis is more common in children, which occurs in 3-4% of children with acute rhinosinusitis.<sup>2,3,4</sup>

Anatomy of the eye is closely related to the sinuses, especially the maxillary, ethmoid and frontal sinuses. The optic canal is also adjacent to the ethmoid and posterior sphenoid sinuses, lamina papyracea in children is a thin bony plate located between the eye and the ethmoid sinus, which has many dehiscences.<sup>5</sup> The nasal cavity in children tends to be narrower and have softer mucosa, which makes the sinuses easily blocked by mucosal edema during acute infection, and causes the infection to spread from the sinuses to the eye.<sup>2,5</sup>

## Case

A 4 year old child presented with eye swelling and pus discharge in the right eye since 5 days before admitted to the hospital. Two weeks



**Figure 1.** (A) A 4 year old patient with right orbital abscess extending to the lower lid and causing proptosis. (B) Computed tomography (CT) findings demonstrating contrast enhancement in intraorbital suspecting intraorbital abscess with orbital cellulitis, right pansinusitis and buccal abscess. (C) The same patient 7 days after endoscopic sinus surgery and antimicrobial therapy.

Nasoendoscopy was not performed because the patient was not cooperative. Eye examination shows edema in the superior and inferior palpebra, conjunctival chemosis, hyperemia, restricted movement, proptosis and decreased vision in the right eye (1 / ~). CT scan revealed contrast enhancement in intraorbital with suspected intraorbital abscess with orbital cellulitis, right pansinusitis and buccal abscess. An MRI was also performed and revealed to support an intraorbital abscess formation. Patient was given ceftriaxone, metronidazole, ketorolac, and immediate functional endoscopic sinus surgery was done.

Intraoperatively found the middle meatus covered with mucopurulent secret, unsinectomy and middle meatus antrostomy was performed and shows the maxillary sinus was filled with pus and then cleaned, etmoidectomy anterior and posterior was performed until lamina papyracea is completely exposed. Lamina papyracea was then removed, the periorbita was opened to reveal orbital fat. The intra

orbital abscess bag was opened and the pus was obtained approximately 5cc. An aspiration of the buccal abscess was done and there was 5cc of pus.

First day of postoperative the orbital edema was reduced, and the vision was improved 6/60. Third day of postoperative a nasal toilet was performed under general anesthesia, an open meatus medius was obtained, purulent secretions (+), an open maxillary sinuses with minimal mucoid secretions. Sixth day of postoperative there is a minimal palpebral edema, and vision was restored to normal. The nasal toilet was done under anesthesia shows an open meatus medius with no secretion, the orbital fat was intact, and an open maxillary sinuses. Patient was discharged on the seventh postoperative day with oral therapy and nasal irrigation using NaCl 0,9% 30 cc thrice a day. Follow up on the fourteenth day after surgery found no orbital edema, open middle meatus with no secretions, and normal vision 6/6

## Discussion

Rhinosinusitis is defined as inflammation of the nose and the paranasal sinuses characterized by two or more symptoms, one of which should be either nasal blockage/ obstruction/ congestion or nasal discharge (anterior/posterior) +/- facial pain +/- reduction or loss of smell, and either endoscopic signs of nasal polyps and/or mucopurulent discharge from and/or mucopurulent discharge from middle meatus and/or oedema/ mucosal obstruction primarily in middle meatus, and/or mucosal changes within ostiomeatal and/or mucosal changes within ostiomeatal complex and/or sinuses revealed in CT scan EPOS 2020).

Orbital complications associated with acute rhinosinusitis are common in children, accounting for 80% of all complications, and can cause permanent appropriately. The severity of orbital according to Chandler's<sup>4</sup> classification :

1. Periorbital cellulitis : inflammation of the eyelids characterized by edema of the eyelids.
2. Orbital cellulitis : inflammation and edema have extended to the orbit, characterized by proptosis, chemosis and impaired eye movement. Usually can extend to orbital abscess and blindness.
3. Periorbital abscess (subperiosteal abscess): A formation and collection of pus between the periorbita and the orbital bony wall, which characterized by proptosis with changes in the position of the eyeball, impaired eye movement and decreased vision.
4. Orbital abscess : A formation and collection of pus in the orbit characterized by ophthalmoplegia, proptosis and loss of vision
5. Cavernous sinus thrombosis : there has been an extension of infection to

the cavernous sinus which characterized by proptosis, ophthalmoplegia, loss of vision accompanied by expansion of signs of infection to healthy eyes and signs of meningitis.

Emergency surgical intervention are indicated in cases of children with large superiosteal abscess or orbital abscess, severe proptosis, ophthalmoplegi, decreased vision and presence of afferent papillary defect.<sup>2,5,6</sup>

Indications for immediate surgery in this case are decreased vision, proptosis and ophthalmoplegia, and the presence of a suspected intraorbital abscess which demonstrated by CT scan. This is also consistent with Sara et al<sup>2</sup> who stated that orbital abscess and subperiosteal abscess are considered emergency cases and are usually treated with immediate surgical drainage to prevent permanent blindness, possible intracranial complications and death. The purpose of the surgery are to drain the abscess, restore intraorbital pressure and restore the sinonasal complex drainage, also to obtain samples for culture. The surgical steps include uncinectomy, antrostomy, etmoidectomy, and penetration of the lamina papyracea. This procedure has several advantages over open procedures, namely eliminating external wounds, reducing postoperative edema, and faster recovery. The success of the transnasal endoscopic approach depends on the expertise of the ENT doctor, amount of local bleeding and the paranasal sinuses involved. According to Yuzhu et al<sup>7</sup>, who performed transnasal endoscopic approach in patients with orbital abscesses, they experienced a total improvement approximately 4 to 8 days after surgery.

Conservative treatment can generally be given to patients with Chandler categories 1 to 3. In subperiosteal abscesses with minimal orbital symptoms and abscess size less than 10 mm, conservative therapy is administered and monitored over 24 to 48 hours. If worsening or no improvement within 48 hours, a CT scan needs to be repeated and surgery is

performed immediately. Where as in cases of preseptal cellulitis, the initial treatment is parenteral antibiotic therapy. Conservative treatment with close clinical monitoring may also be considered in cases of orbital cellulitis without visual disturbances or elevated intraocular pressure, with surgical options if worsening or no improvement after 48 hours.

Antimicrobial therapy must cover the causative organism and have sufficient penetration capability into the central nervous system to reduce the risk of intracranial complications.<sup>8</sup> The patient given ceftriaxone in combination with metronidazole intravenously, consistent with most recommendations suggesting a multi-drug combination or a single broad-spectrum antibiotic, to cover polymicrobial pathogens including anaerobes.<sup>8,9</sup> Empirical therapy that can be given is a combination of clindamycin and third generation cephalosporins, vancomycin with or without meropenem, ampicillin-sulbactam, and third generation cephalosporins with metronidazole.<sup>2,9</sup> The patient also given adjunction corticosteroid therapy, this is in accordance with the guidelines for the management of the Infectious Diseases Society of America

(IDSA) which recommends giving corticosteroids as an adjunct therapy, especially in patients with a history of allergic rhinitis, and does not recommend giving oral or topical decongestants.<sup>10</sup>

Oral antimicrobial therapy is given according to the results of culture, while patients who did not undergo surgery were given amoxicillin with clavulanic acid or clindamycin for 2 weeks.<sup>10,11</sup>

## Conclusion

Orbital complication due to acute rhinosinusitis are uncommon but potentially lead to more fatal complications, therefore requires an aggressive approach. Any case with suspected orbital infection should be treated with antimicrobial therapy and close monitoring. High doses of broad spectrum antimicrobial therapy and steroids should be given immediately in cases of orbital complications with pre-septal cellulitis or periosteal abscess, however, orbital abscess is generally requires surgical approach. Endoscopic sinus surgery gives excellent results if done with good technique and appropriate postoperative care.

## References

1. Singh SK, James E, Sabarigirish K, Swami H, Sood T. Bilateral orbital complications of paediatric rhinosinusitis. *Med J Armed Forces India*. 2014;70:68–72. <https://doi.org/10.1016/j.mjafi.2012.11.015>
2. Sara Torretta, Claudio Guastella PM. jcm-08-00101.pdf. *Sinonasal-Related Orbital Infect Child A Clin Ther Overv*. 2018;9.
3. Kaya K, Yegin Y, Olgun B. Anatomical Factors in Children with Orbital Complications Due to Acute Rhinosinusitis. 2019;3.
4. Badr, D., Gaffin, J. and Phipatanakul. *Pediatric Rhinosinusitis*. 2017;4:268–281
5. Pradhan P, Samal DK, Preetam C, Parida PK. Intraorbital and intracranial complications of acute rhinosinusitis: A rare case report. *Iran J Otorhinolaryngol*. 2018;30:301–4.
6. Surgery AA of O-H and N. Diagnostic Criteria for Rhinosinusitis. *Clin Pract Guidel AAO*. 2015;12.
7. Wan, Y., Shi, G. and Wang, H. Treatment of Orbital Complications Following Acute Rhinosinusitis in Children. 2016;33:401-6.
8. Drago L, Pignataro L, Torretta S. Microbiological Aspects of Acute and Chronic Pediatric Rhinosinusitis. *J Clin Med*. 2019;8:149. <https://doi.org/10.3390/jcm8020149>
9. Chang YS, Chen PL, Hung JH, Chen HY, Lai CC, Ou CY, et al. Orbital complications of paranasal sinusitis in Taiwan, 1988 through 2015: Acute ophthalmological manifestations, diagnosis, and management. *PLoS One*. 2017;12:1–14. <https://doi.org/10.1371/journal.pone.0184477>
10. Chow AW, Benninger MS, Brook I, Brozek JL, Goldstein EJC, Hicks LA, et al. IDSA GUIDELINES IDSA Clinical Practice Guideline for Acute Bacterial Rhinosinusitis in Children and Adults. 2012;54:1041–5.
11. Wan, Y., Shi, G. and Wang, H. Treatment of Orbital Complications Following Acute Rhinosinusitis in Children. 2016;33:401-6.

The authors declared that all the images and figures in this manuscript are author's own work and hasobtained necessary permission from the patient parents.



(Michael)