

Late Intra-Uterine Fetal Demise with Fetal Hydrops: Challenges of Management Planning in Indonesia

Gezta Nasafir Hermawan¹, Jacobus Jen0 Wibisono¹, Julita D.L. Nainggolan¹

¹*Department of Obstetrics and Gynecology, Faculty of Medicine, Pelita Harapan University/Siloam Hospitals Lippo Village*

Abstract:

Intra-Uterine Fetal Demise (IUFD) is defined as death of human conception at age of 20 weeks' gestation or older or with a minimum 500-g birthweight before complete delivery from the mother and induced termination involved. In 2015, Indonesia has contributed a stillbirth rate of 13 out of 1,000 total births in which 17.1% of the cases were caused by congenital anomalies. Fetal Hydrops as a pathological condition in which there is an accumulation of fluid in fetal soft tissues and serous cavities. With the advancements of sonographic technology, identification of fetal hydrops has become uncomplicated. However, what remains a challenge is to investigate etiology and determine management. In order to plan proper management, the etiology of fetal hydrops must first be determined to predict the prognosis of fetal hydrops. In Indonesia; limited facilities and experts combined with high costs in etiology determination and management have complicated the matter. Furthermore, the strong influence of several Eastern communities' norms and religious views have further complicated both physicians and patients in decision making. In this report, we present a case of late intra-uterine fetal demise with fetal hydrops, whom was admitted on her 35 weeks age gestation. We performed elective Caesarean Section in order to deliver the stillborn fetus, with no significant post-operative complication. Unfortunately, this condition was actually diagnosed earlier during 20th weeks of gestation, hence advised to continue the pregnancy without further evaluation and information to the mother regarding the hydrops condition.

Citation : Hermawan Gezta Nasafir, Wibisono Jacobus Jen0, Nainggolan Julita D.L. Late Intra-Uterine Fetal Demise with Fetal Hydrops: Challenges of Management Planning in Indonesia
Medicinus. 2020 June; 8(2):81-93
Keywords: Intra-Uterine Fetal Demise; Fetal Hydrops; Management; Planning.
***Correspondance** : Gezta Nasafir Hermawan.
E-mail : getza.hermawan@gmail.com
Online First : April 2021

Introduction

Intra-Uterine Fetal Demise/Death (IUFD) or Stillbirth is a generally defined by World Health Organization (WHO) and American College of Obstetrics and Gynecology (ACOG) as death of human conception/fetus at age of 20 weeks' gestation or older or with a minimum 500-g birthweight, which occurs before complete delivery/expulsion/extraction from the

mother and not considered as an induced termination of pregnancy. The term is further classified into different periods as: early/intermediate IUFD, if completed 20-27 weeks of gestation; and late IUFD, if completed 28 weeks of gestation and more.^[1] Based on the data acquired by United Nation International Children's Emergency Fund (UNICEF) in 2015, Indonesia has contributed a neonatal mortality rate of 14 out of 1,000 total births

with a stillbirth rate of 13 out of 1,000 total births; the main causes of neonatal deaths in 2015 were prematurity (35,5%), birth asphyxia and trauma (21,6%), and congenital anomalies (17,1%).^[2]

One condition of congenital anomalies associated with high fetal mortality is fetal hydrops. Fetal Hydrops or *Hydrops Fetalis* is described as a pathological condition in which there is an accumulation of fluid in fetal soft tissues (generalized skin edema) and serous cavities (commonly in peritoneal, pleural and pericardial cavities);

This condition is often associated with placental thickening (placentomegaly) and polyhydramnios.^[1,4,5] Currently, fetal hydrops is further divided into two etiological groups: (1) Immune Fetal Hydrops (IFH), associated with red cell alloimmunization; and (2) Non-Immune Fetal Hydrops (NIFH), mostly associated with abnormalities of: cardiovascular (20%), chromosomal (13%) and hematologic (12% cases, with alpha thalassemia accounts for 28-55% of case in Southeast Asia).^[6]

Cause	Cases	Mechanism
Cardiovascular	17-35%	Increased central venous pressure
Chromosomal	7-16%	Cardiac anomalies, lymphatic dysplasia, abnormal myelopoiesis
Hematologic	4-12%	Anemia, high output cardiac failure; hypoxia (alpha thalassemia)
Infectious	5-7%	Anemia, anoxia, endothelial cell damage, and increased capillary permeability
Thoracic	6%	Vena caval obstruction or increased intrathoracic pressure with impaired venous return
Twin-twin transfusion	3-10%	Hypervolemia and increased central venous pressure
Urinary tract abnormalities	2-3%	Urinary ascites; nephrotic syndrome with hypoproteinemia
Gastrointestinal	0.5-4%	Obstruction of venous return; gastrointestinal obstruction and infarction with protein loss and decreased colloid osmotic pressure
Lymphatic dysplasia	5-6%	Impaired venous return
Tumors, including chorioangiomas	2-3%	Anemia, high output cardiac failure, hypoproteinemia
Skeletal dysplasias	3-4%	Hepatomegaly, hypoproteinemia, impaired venous return
Syndromic	3-4%	Various
Inborn errors of metabolism	1-2%	Visceromegaly and obstruction of venous return, decreased erythropoiesis and anemia, and/or hypoproteinemia
Miscellaneous	3-15%	
Unknown	15-25%	

SMFM. Nonimmune hydrops fetalis. Am J Obstet Gynecol 2015.

Table 1.

Etiologies of Non-Immune Fetal Hydrops (Society of Maternal-Fetal Medicine Clinical Guideline, 2015)

Many studies have proven that fetal hydrops is a serious life-threatening condition for both fetal and maternal health. A retrospective study conducted by Yeom W et al (2005-2013) in Samsung Medical Center South Korea found 42 cases of fetal hydrops were identified out of 17,217 deliveries (24.4 per 10,000 deliveries); 23 of

those fetal hydrops case died (4 IUFDs and 19 Neonatal Deaths, overall neonatal mortality rate 54.0%); 3 of those cases were electively terminated, with only 16 cases survived.^[3] A similar study shows high fetal mortality rate (60% in NIFH) and low survival rate of less than 50% (almost two-thirds do not survive) with only 25%

survived without major morbidities. [7] One maternal complication most often

associated with fetal hydrops is mirror syndrome with overall rate of intrauterine death was 56%, and maternal morbidity risk of pulmonary edema in 21.4% cases with symptoms disappeared 4.8-13.5 days after delivery. Based on these studies, early diagnosis and giving proper management for fetal hydrops is fundamental and significant.

Identification of fetal hydrops has become uncomplicated with the advancements of sonographic technology throughout the past four decades. However, what remains a challenge is to investigate etiology and determine appropriate management for the pregnancy. Proper management, which ranges from referral for sub-specialty treatments to termination of pregnancy can only be decided upon knowing the prognostic predictor of fetal hydrops (gestational age and etiology); this makes determining etiology a mandatory first process prior to management planning. In Indonesia however, clinical considerations are made complicated due to: (1) limited availability of facilities and experts capable of evaluating etiology and executing proper management for fetal hydrops; (2) complex referral procedure to those facilities; and (3) Eastern norms and religious views toward controversial procedures that they deemed as a taboo (e.g. termination). These complicated matters of consideration have made it difficult for patients and physicians to decide what's best for the pregnancy.

Case Summary

A 21-year old (gravida 1, para 0, abortus 0) on her 35th week of gestation came for the first time to our outpatient department in Siloam Public Hospital Lippo Village for prenatal check-up. The patient had done several prenatal check-ups, once in each

first, second and third trimester in another hospital by an obstetric and gynecologic specialist. She recalled that during previous 2D-ultrasound examinations done in another hospital; no major anatomic abnormalities were discovered during the first trimester; anatomical abnormalities became significantly visible during the second and third trimesters. The obstetrics and gynecology specialist advised the patient to return every month for follow-up prenatal examinations regarding the abnormal anatomical condition. The patient had previously done laboratory blood hemoglobin (Hb) examination during her sixth week of gestation to which her Hb was 10,1 g/dL which was considerably low; previous urine dipstick, Hepatitis B Surface Antigen (HbsAg), and anti-HIV showed no significant abnormalities. She denied having previously tested for TORCH (Toxoplasma, Rubella, Cytomegalovirus and Herpes). The patient admitted that she consumes routine folic acid and ferrous sulfate medication. Throughout the recent two-weeks before she came to our outpatient department, the patient complaint that her stomach felt distended and no fetal movements were felt.

2D-Ultrasound imaging was performed in our clinic, revealed a single intrauterine pregnancy in transverse lie position, with absent fetal heartbeat and fetal movement suggestive of intrauterine fetal demise, biometry was appropriate to 35 weeks of gestation (according to Head Circumference in Hadlock Standard). Scalp edema [Figure 1], pericardial effusion [Figure 2], pleural effusion/hydrothorax [Figure 2 and 3] and ascites [Figure 4] were noted suggestive of fetal hydrops. Polyhydramnios was highlighted with Maximum Vertical Pocket (MVP) measured 122,8 mm (normal 20 - 80 mm) [Figure 5]. 4D-Real Time Rendering was done, severe scalp and facial edema; facial cleft; and no fetal movement was observed [Figure 6].

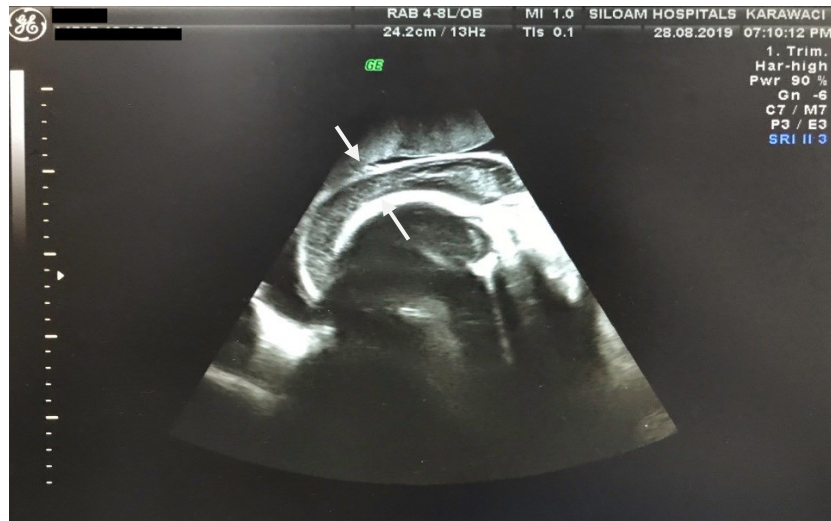

Figure 1.

2D Transabdominal Ultrasound showed extracranial scalp edema (between arrows) of the fetal head at 35 weeks' gestation. (the patient has consented for usage in this case report)

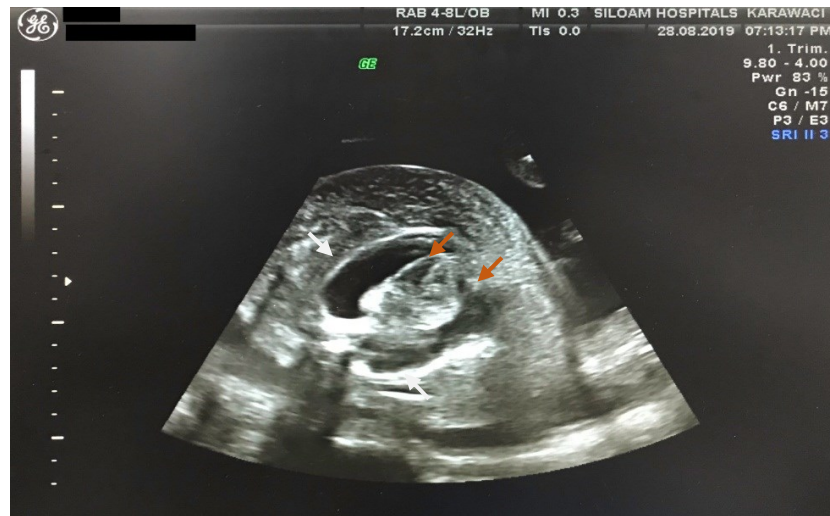

Figure 2.

2D Transabdominal Ultrasound cross-sectional view of the fetal thoracic cavity at 35 weeks' gestation. Note slight pericardial effusion (brown arrows) and bilateral pleural effusion (white arrows).(the patient has consented for usage in this case report)

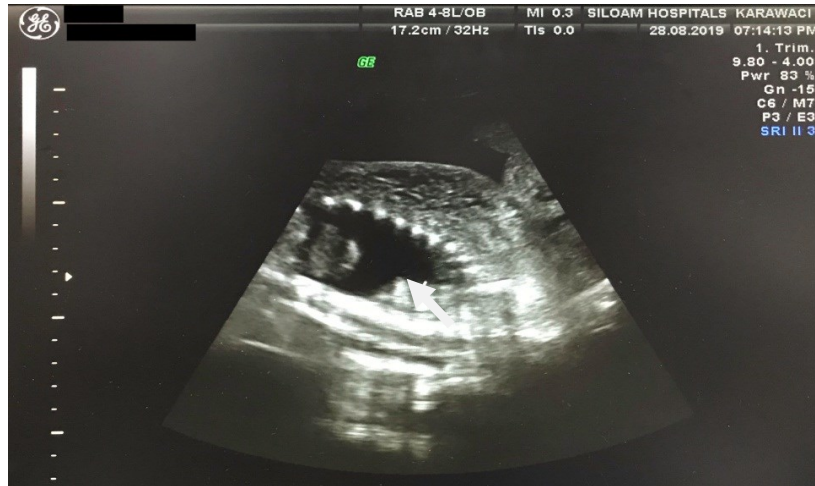

Figure 3.

2D Transabdominal Ultrasound longitudinal view of fetal thoracic cavity at 35 weeks' gestation. Note pleural effusion and hydrothorax (white arrow). (the patient has consented for usage in this case report)

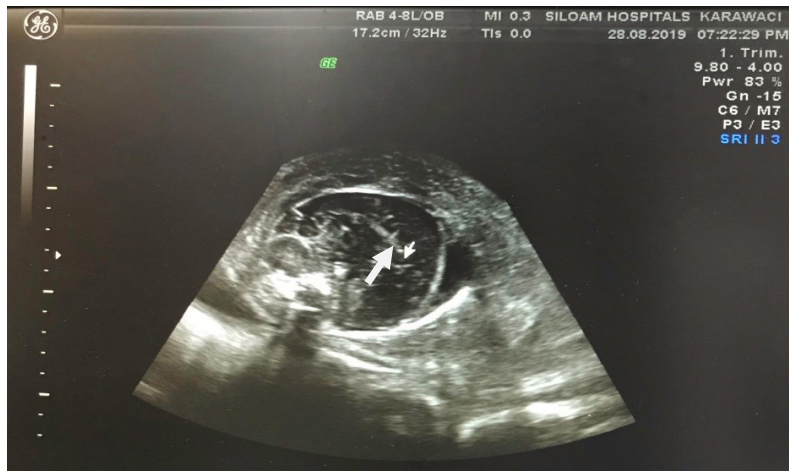

Figure 4.

2D Transabdominal Ultrasound cross-sectional view of fetal abdominal cavity at 35 weeks' gestation. Note ascites (white arrow). (the patient has consented for usage in this case report)

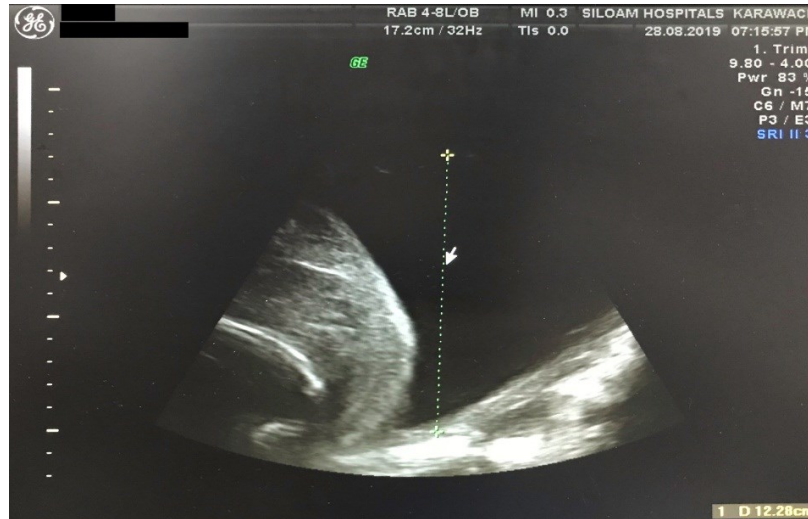


Figure 5.

2D Transabdominal Ultrasound longitudinal view of the patient's intrauterine cavity. Maximum Vertical Pocket (MVP) measured 122,8 mm (normal 20 - 80 mm) signified polyhydramnios. (the patient has consented for usage in this case report)

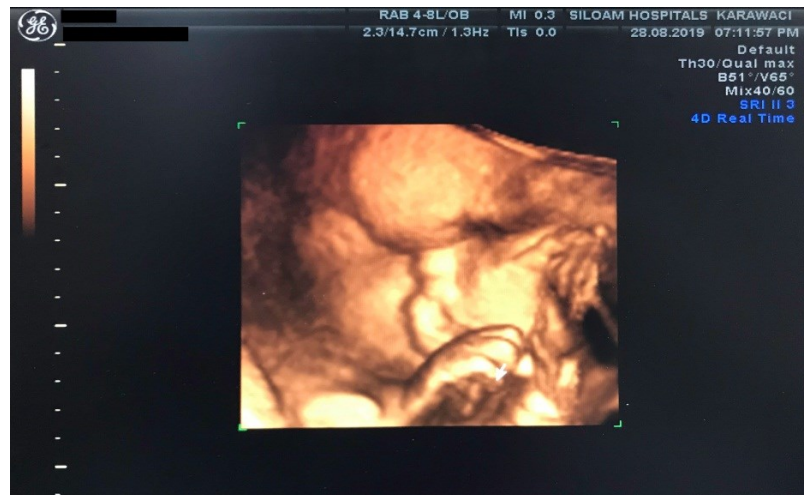

Figure 6.

4D Real Time Rendering Ultrasound of the fetal face at 35 weeks' gestation. Note severe scalp and facial edema with facial cleft. No fetal movement was observed. (the patient has consented for usage in this case report)

Given the severity of the clinical picture, the patient was convinced to undergo elective caesarean section with the indication of transverse fetal lie based on ultrasonography imaging. Maternal pre-operative complete blood count was performed in which the patient has low hemoglobin (Hb) of 10.20 g/dL (normal 11.70 - 15.50 g/dL), hematocrit (Ht) of 31.10 % (normal 35.00 - 47.00 %), Erythrocyte (RBC) of 4.99 millions/uL, mean corpuscular volume (MCV) of 62.32 fL (normal 80.00 - 100.00 fL), mean corpuscular hemoglobin (MCH) of 20.44 pq (normal 26.00 - 34.00 pq), and mean corpuscular hemoglobin concentration (MCHC) of 32,7 g/dL suggestive of microcytic hypochromic anemia. The Mentzer index which is a ratio equivalent to MCV (fL) divided by RBC

(millions/uL) for this patient is 12,70 suggestive of possible thalassemia trait (Mentzer Index <14 suggestive of thalassemia, >14 suggestive of iron deficiency anemia). At birth, the macerated late stillborn at 35 weeks' gestation with fetal weight of 3175 grams and head circumference of 40 cm presented with severe hydrops, cyanotic, apneic with no movement observed [Figure 7]. The placenta was edematous and large. Further post-mortem fetal laboratory and evaluation was not performed. Post-operative course was uneventful. The patient and her husband was counselled to take complete hematologic, immunologic and if necessary seek for genetic counseling before the next pregnancies to come.

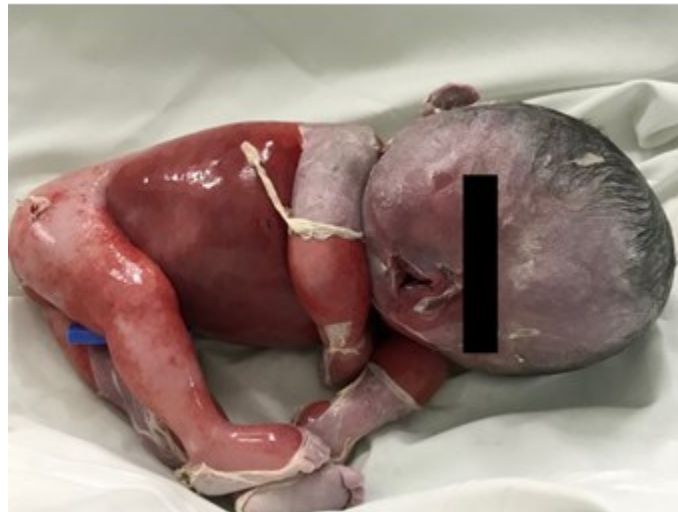

Figure 7.

Post-delivery via Caesarean Section showed macerated late stillborn infant at 35 weeks' gestation presented with severe hydrops, cyanotic, and apneic with no fetal movement observed.(the patient has consented for usage in this case report)

Discussion

The diagnosis of fetal hydrops can be made on the basis of 2D-Transabdominal/gray-scale ultrasonography as showed in Figure 1-5. The diagnosis of fetal hydrops is made if accumulation of fluid can be found in at least two interstitial cavities (pericardial, pleural, or peritoneal) or in one cavity plus generalized edema/anasarca. In order to plan for proper management, The Society of Maternal-Fetal Medicine Clinical Guideline mentioned that decisions will depend on the gestational age and etiology in which the cause is treatable or untreatable, hence determining specific etiology of fetal hydrops is truly necessary.^[4] Etiology determination of fetal hydrops require several examinations which includes: hematology (Blood Count, Indirect COOMBS Test, G6PD Test, and Hemoglobin Electrophoresis to rule out any inborn error of metabolism and thalassemia hemoglobinopathy), amniocentesis (Fetal karyotyping for B19 parvovirus, cytomegalovirus, and toxoplasmosis to rule out those infections respectively), and genetic profiling (Chromosome Analysis for fetal anomalies).^[1,4]

Proper referral and early effective management in capable facilities will reduce both maternal (e.g. Mirror Syndrome) and fetal (e.g. intra-uterine fetal death) complications, which will be discussed further. In spite of that, determining specific etiology is still a challenge in Indonesia due to: limited availability of facilities, experts, high costs and complex referral procedure to those facilities. Not all facilities are capable of performing the examinations mentioned above due to lack of technologies and experts (e.g. fetal-maternal subs-specialists for amniocentesis). Referral to ideal facilities with capable technologies and experts (e.g. Harapan Kita Fetal-Maternal Center in Jakarta) can be complicated due to geographical proximity (far distance) from many referring facilities, especially those

located outside Jakarta. This makes the patient to consider not to be referred and instead be managed in local or current facilities with limited capabilities. Furthermore, some of the examinations mentioned above are expensive and are not covered by national health insurance; hence, this reality reduced the willingness of a majority of patients with lower socioeconomic class to be referred to ideal facilities. For this patient, we could only perform complete blood count and microcytic hypochromic anemia was noted, other examinations were not performed due to restricted economic condition and limited financial coverage. We asked the patient for any suggestions of referral to fetal-maternal experts offered during her previous prenatal check-ups, in which she didn't remember.

Hematologic disorders contributed as the cause of approximately 7-12% of non-immune fetal hydrops (NIFH) cases. One hematologic disorder known to cause immune fetal hydrops (IFH) is blood group alloimmunization, however it only occurred in less 10% of all fetal hydrops cases.^[5] As majority of hematologic disorders more likely to cause non-immune fetal hydrops (NIFH), hemoglobinopathies such as alpha thalassemia accounts for 28-55% of cases in Southeast Asia.^[5] Alpha-thalassemia is primarily caused due to reduction in synthesis of alpha-globulin chains located on chromosome 16p13.3. Mutations or deletions that affect one or more alpha globulin genes, most frequently single-gene deletion or inactivation of only one alpha globulin chain may cause mild hematologic finding known as alpha thalassemia carrier. Inactivation of two alpha globulin chains results in a mild microcytic hypochromic with normal or altered Hb A2 levels, a condition known as alpha thalassemia trait.^[8] The Mentzer index is one predictive indicator of thalassemia trait possibility (Sensitivity/Sn 0.36, Specificity/Sp 0.81, positive predictive value/PPV 0.44 and negative predictive value/NPV 0.75), calculated as a ratio equivalent to MCV (fL)

divided by RBC (millions/uL) (Mentzer Index <14 suggestive of thalassemia, >14 suggestive of iron deficiency anemia). [9] Definite diagnosis of thalassemia cannot be determined only by this predictive indicator, further hematologic examinations such as iron profiling (serum iron, total iron binding capacity and serum ferritin), hemoglobin electrophoresis and if possible cytogenetic evaluation is still necessary to exclude other possibility of mild microcytic hypochromic anemia etiology (iron deficiency anemia/IDA) and to determine hemoglobinopathy types (thalassemia types). [1,4] In this patient, Mentzer Index of

12,70 is obtained, which suggests a possibility of thalassemia trait in the patient. We still cannot determine definite etiology of fetal hydrops in this case, since other examinations couldn't be performed due to restricted economic condition and limited financial coverage as mentioned above. Post mortem detailed anatomic survey of the infant is also necessary as additional information can be gathered to determine specific etiology of fetal hydrops. [1] Unfortunately, in this case, the patient (mother) refused for the infant to undergo further examinations.

Etiology	Therapy	Recommendation
Cardiac tachyarrhythmia, supraventricular tachycardia, atrial flutter, or atrial fibrillation	Maternal transplacental administration of antiarrhythmic medication(s)	Treatment with antiarrhythmic medication unless gestational age is close to term or there is maternal or obstetrical contraindication to therapy
Fetal anemia secondary to parvovirus infection or fetomaternal hemorrhage	Fetal blood sampling followed by intrauterine transfusion	Fetal intrauterine transfusion if anemia is confirmed, unless pregnancy is at an advanced gestational age and risks associated with delivery are considered to be less than those associated with delivery are considered to be less than those associated with procedure
Fetal hydrothorax, chylothorax, or large pleural effusion associated with bronchopulmonary sequestration	Fetal needle drainage or effusion or placement of thoracoamniotic shunt; if gestational age is advanced, needle drainage prior to delivery in selected cases	Consider drainage of large unilateral pleural effusion(s) resulting in NIHF, or, if gestational age is advanced, consideration of needle drainage prior to delivery
Fetal CPAM	<p>Macrocytic type: fetal needle drainage of effusion or placement of thoracoamniotic shunt</p> <p>Microcytic type: maternal administration of corticosteroids, betamethasone 12.5 mg IM q24h x 2 doses or dexamethasone 6.25 mg IM q12h x 4 doses</p>	Consider drainage of large macrocystic CPAM that has resulted in NIHF; if large microcystic CPAM has resulted in NIHF, we suggest that management options include maternal corticosteroid administration
TTTS or TAPS	Laser ablation of placental anastomoses or selective termination	Consideration of fetoscopic laser photocoagulation of placental anastomoses for TTTS or TAPS that has resulted in NIHF < 26 weeks
Twin-reversed arterial perfusion sequence	Percutaneous radiofrequency ablation	Referral for consideration of percutaneous radiofrequency ablation that has resulted in NIHF
<p><i>For each of these etiologies, it is recommended that treatment be performed at tertiary care center or center with expertise in relevant therapy.</i></p> <p>CPAM: congenital pulmonary airway malformation; IM: intramuscular; NIHF: nonimmune hydrops fetalis; TAPS: twin-anemia polycythemia sequence;</p> <p>TTTS: twin-twin transfusion sequence.</p> <p><i>SMFM. Nonimmune hydrops fetalis. Am J Obstet Gynecol 2015.</i></p>		

Table 2.
Therapy for selected etiologies of nonimmune hydrops
(Society for Maternal-Fetal Medicine Clinical Guideline, 2015)

After specific etiology determined, cases generally classified as: (1) amenable to therapy and urgently treatable cases in which treatment [Table 2] or referral to a specialized center is necessary, (2) lethal prognosis cases (other cases not mentioned in Table 2) in which termination might be offered and (3) idiopathic with uncertain but likely poor prognosis in which termination might also be offered.^[4] Note that pregnancy termination should be offered after fetal hydrops is identified and as early as possible before fetus reach viability. Patients amenable to therapy who declines therapy or unable to receive therapy will have poor prognosis. Patients with treatable or non-lethal etiology of fetal hydrops who has reached viable gestational age (28 gestational weeks) is a candidate for antepartum fetal surveillance in order to determine optimal time and mode of delivery. If there is absence in clinical deterioration and complications (e.g. mirror syndrome), delivery by 37-38 weeks should be considered. Mirror syndrome also known as Ballantyne's syndrome is one maternal complication of fetal hydrops in which the mother develops edema that "mirror" that of her hydropic fetus; characterized by edema in approximately 90%, hypertension in 60%, and proteinuria in 40% similar to preeclampsia; with overall rate of intrauterine death was 56%, and maternal risk of pulmonary edema in 21.4% cases; symptoms disappeared 4.8-13.5 days after delivery. ^[1,4,10] Fetuses with hydrops are at high risk of preterm delivery and hemodynamic compromise, hence corticosteroid treatment is reasonable from gestational age 24-34 weeks if the etiology is deemed non-lethal and if intervention (Table 2) planned.

Management planning for fetal hydrops in Indonesia is also challenging and complicated due to Eastern norms and religious views toward controversial procedures such as termination of pregnancy, which is considered as an act of murder and therefore it cannot be tolerated even with medical indication. The

challenges that most physicians face during management planning for fetal hydrops are as follows: (1) if they found out that the etiology of the patient is amenable to treatment, some patient would most likely refuse due to high costs and far distance of referral as mentioned above; (2) In the contrary, if they found out that the etiology of the fetal hydrops has lethal prognosis or idiopathic with uncertain prognosis in which termination could be offered, some physicians hesitate to offer that option due to norms and religious views and some patient would most likely to refuse as well. Hence, the dilemma still persists until now.

We believe that in this complicated and challenging condition, proper counselling to the patient must still be done; since the patient still has the right to know about her condition, and therefore this could prevent misunderstanding, confusion and disappointments. Counselling for pregnancies with fetal hydrops should include potential risk, benefits, and possible alternatives of intervention and possible regarding the underlying condition. Hence, the patient in our case has the right to know about the condition. ^[4]

Optimal mode of delivery depends on findings of antepartum surveillance, drainage of large effusion may improve efficacy of neonatal resuscitation, vaginal delivery is preferred unless otherwise contraindicated. ^[4] In this patient, caesarean delivery is preferred since the fetus is in transverse lie which is an absolute indication. ^[1] Delivery in a center with neonatal intensive-care unit must be considered if the fetal hydrops has an idiopathic etiology and potentially require postnatal treatment. ^[4] For future pregnancies, the patient was advised to do routine prenatal screening, complete hematological screening (complete blood count, red cell index, iron profiling, and Hb electrophoresis), immunological infection screening (TORCH and Parvovirus B19), if possible cytogenetic evaluation and genetic counselling to prevent similar consequences. ^[1,4,5]

Conclusion

Identification of fetal hydrops has become uncomplicated with the advancements of sonographic technology throughout the past four decades, however what remains a challenge is to investigate etiology and determine appropriate approach for the pregnancy. Since appropriate approach and therapy can only be achievable by first determining the specific etiology, hence etiology evaluation of fetal hydrops is fundamental. In Indonesia however, clinical considerations are made complicated due to: limited availability of facilities and experts

capable of evaluating etiology and executing proper management for fetal hydrops; complex referral procedure to those facilities; and Eastern norms and religious views toward controversial procedures that they deemed as a taboo (e.g. termination).

Even with all its difficulties, counselling for pregnancies with fetal hydrops is still necessary; and counselling should include potential risk, benefits, and possible alternatives of intervention possible regarding the underlying condition; since the patient still has the right to know about her pregnancy condition.


References

1. Williams JW, Cunningham FG, Leveno KJ, Bloom SL, Dashe JS, Hoffman BL et al. Williams obstetrics. 24th ed. New York: McGraw-Hill Education; 2014.
2. Maternal and Neonatal Health Disparities Indonesia. UNICEF; 2015.
3. Yeom W, Paik E, An J, Oh S, Choi S, Roh C et al. Clinical characteristics and perinatal outcome of fetal hydrops [Internet]. *ogscience.org*. 2019 [cited 22 September 2019]. Available from: <http://dx.doi.org/10.5468/ogs.2015.58.2.90>
<https://doi.org/10.5468/ogs.2015.58.2.90>
4. Norton M, Chauhan S, Dashe J. Society for Maternal-Fetal Medicine (SMFM) Clinical Guideline #7: nonimmune hydrops fetalis [Internet]. *American Journal of Obstetrics and Gynecology*. 2015 [cited 15 September 2019]. Available from: <http://dx.doi.org/10.1016/j.ajog.2014.12.018>
<https://doi.org/10.1016/j.ajog.2014.12.018>
5. Callen P, Feldstein V, Norton M, Scoutt L. Callen's ultrasonography in obstetrics and gynecology. 6th ed. Philadelphia: Elsevier; 2017.
6. Liao C, Wei J, Li Q, Li J, Li L, Li D. Nonimmune hydrops fetalis diagnosed during the second half of pregnancy in Southern China. *Fetal Diagn Ther* 2007;22:302-5
<https://doi.org/10.1159/000100796>
7. Czernik C, Proquitté H, Metze B, Bühner C. Hydrops fetalis: has there been a change in diagnostic spectrum and mortality? *J Matern Fetal Neonatal Med* 2011;24:258-63
<https://doi.org/10.3109/14767058.2010.483522>
8. Akar M, Dilli D, Dilmen U. A Case of Nonimmune Hydrops Fetalis Caused by Homozygous α -Thalassemia. *Turkish Journal of Hematology*. 2013;30(1):63-65.
<https://doi.org/10.4274/tjh.2012.0021>
9. Siswandari W, Rujito L, Indriani V, Djatmiko W. Mentzer Index Diagnostic Value in Predicting Thalassemia Diagnosis. *IOP Conference Series: Earth and Environmental Science*. 2019;255:012004.
<https://doi.org/10.1088/1755-1315/255/1/012004>
10. Braun T, Brauer M, Fuchs I, Czernik C, Dudenhausen J, Henrich W et al. Mirror Syndrome: A Systematic Review of Fetal Associated Conditions, Maternal Presentation and Perinatal Outcome. *Fetal Diagnosis and Therapy*. 2010;27(4):191-203.
<https://doi.org/10.1159/000305096>

Author's Statement

The authors declared that all the images and figures in this manuscript is/are author's own work and/or has obtained necessary permission to re-use the content from the patients, authors and publisher of respective materials.

Signature,

A handwritten signature in black ink, appearing to read 'Gezta Nasafir Hermawan', enclosed in a thin black rectangular border.

Gezta Nasafir Hermawan