

Challenge as Physician to Diagnose Pediatric Patient with Laryngopharyngeal Reflux: A case report and literature review

Aris Rahmanda¹, Niken Ageng Rizki²

¹Faculty of Medicine, Pelita Harapan University, Boulevard Jendral Sudirman street, Karawaci, Tangerang, Indonesia 15811

²Department of Otorhinolaryngology, Faculty of Medicine, Pelita Harapan University, Boulevard Jendral Sudirman street, Karawaci, Tangerang, Indonesia 15811

Abstract

Citation : Rahmanda Aris, Ageng Rizki Niken. Challenge as Physician to Diagnose Pediatric Patient with Laryngopharyngeal Reflux: A case report and literature review *Medicinus*. 2020 February; 8(1): 22-30

Keywords: Fiber-optic laryngoscopy, laryngopharyngeal reflux, pediatric, proton pump inhibitor, pneumonia, stridor.

***Correspondance :** Niken Ageng Rizki; Department of Otorhinolaryngology, Faculty of Medicine, Pelita Harapan University, Boulevard Jendral Sudirman street, Karawaci, Tangerang, Indonesia 15811

E-mail : niken.rizki@lecturer.uph.edu

Online First : January 2021

Background : Laryngopharyngeal reflux (LPR) is the reflux of backflow of gastric acid or refluxate that usually affects the throat and laryngopharynx. Many physicians are unable to differentiate between pediatric LPR with pneumonia. Laryngopharyngeal reflux needs to be widely known and understood by a physician because there are relationships between upper and lower airway disease. In pediatric, LPR may also contribute to many problems in the respiratory tract, the clinical manifestation of pediatric LPR, and remains a challenge for physicians.

Objective : To emphasize the new diagnostic symptoms and signs instrument for pediatric LPR using a fiber-optic laryngoscope, also to remind the correlation between the upper and lower respiratory tract and factors which contribute to pediatric airway.

Case : A case of a 21-month-old girl with sudden onset of hoarseness, stridor, and wheezing was diagnosed with pneumonia, further investigation showed reflux symptoms, vocal cord abnormalities, and subglottic edema that suggest LPR was the final diagnosis.

Conclusion : Pediatric LPR may be difficult to diagnose, there are many differential diagnosis, symptoms, and signs that may occur. The new diagnostic instrument can be used for diagnosing pediatric LPR, it is feasible and applicable in daily practice. Laryngopharyngeal reflux needs to be understood and considered as a differential diagnosis for coughing, hoarseness, in children despite the diagnosis challenge.

Introduction

Laryngopharyngeal Reflux (LPR) is defined by the reflux or backflow of either gastric acid or refluxate that containing pepsin into the aerodigestive tract, usually affects the throat and laryngopharynx⁽¹⁾. In general, this disease can be diagnosed with clinical symptoms and further physical examination. The most common symptom of LPR in children is coughing, choking, or hoarseness. Coughing or hoarseness etiology might be hard to differentiate in children, yet children with dysphonia or hoarseness may have reflux as contributing

factors⁽²⁾. Although the incidence of LPR in children is difficult to obtain, about 20% of infants and children are likely to suffer from reflux disease⁽³⁾.

Extraesophageal reflux disease or commonly called LPR can make many complications in pediatrics. Atypical manifestations including stridor, recurring cough, hoarseness, laryngitis, otitis media, sinusitis, chronic bronchitis, asthma, or recurrent pneumonia may occur⁽⁴⁾. LPR also can contribute to developmental failure, laryngomalacia, recurrent respiratory papillomatosis (RRP), chronic cough,

hoarseness, esophagitis, and other

LPR etiology should be able to distinguish between infection, allergies, neoplasms, or other systemic disorders⁽⁶⁾. It is important as a physician to be able to diagnose this disease, overtreatment or overdiagnosis might occur. Below we present a case with laryngopharyngeal reflux diagnose in children with atypical manifestation.

Case Presentation

A 21-month-old girl came to the ENT clinic with complaints of additional breathing sound when she was playing 12 days before admission. Complaints began suddenly when the patient choked while she was eating. There were hoarseness breathing sounds. The hoarseness worsens when the patient cries or after screaming accompanied by coughing. There were stridor and wheezing also appears during sleep. Stertor can be heard when the patient awakes and cries. The previous history was denied. History of sneezing, runny nose, and fever was denied by parents. There is no history of asthma or allergies in patients.

disorders.

Before going to the ENT clinic, the patient was brought by his parents to a pediatrician. On examination, intercostal retractions and epigastric retractions were present, wheezing in both lung fields, dominantly heard in the right lung field. The patient was treated for asthma and was given a combination of salbutamol and steroid inhalation therapy for one week. Seven days after the first therapy was given, the patient's condition did not improve, the patient also had a chest X-ray and a full blood laboratory examination with serum immunoglobulins Covid-19. On X-ray examination found infiltrates in the right lung field, current working diagnosis is community-acquired pneumonia, treated with antibiotic therapy, Azithromycin was given for 5 days. The patient still did not show any improvement in clinical symptoms after antibiotic therapy, the patient was then referred to an ENT specialist.

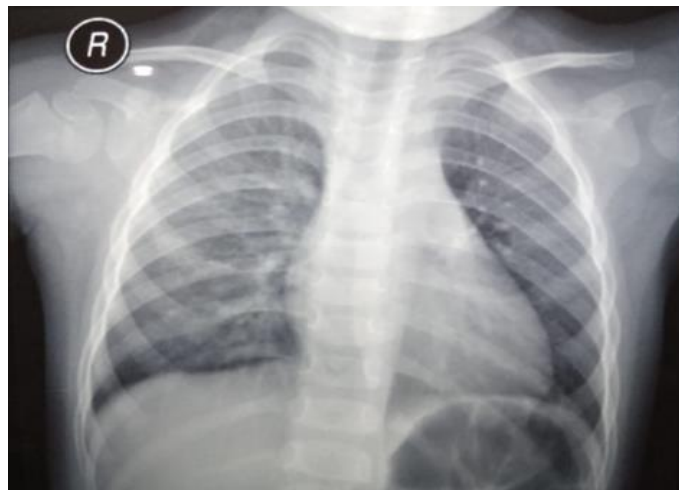


Figure 1. Patient's X-ray showing infiltrates in the right lung field.

The patient came to the ENT clinic, the patient was compos mentis, and vital signs within normal limits. The patient's nutritional status was normal. On physical examination, there was clear stertor heard when the patient was calm. Patients underwent fiber-optic laryngoscopy examination. The results were found a narrow nasal cavity, livid edema of inferior nasal concha, postnasal drip was present, nasopharyngeal oropharyngeal mucosa and there is no enlarged adenoid, visible standing secretion in the piriformis and

vallecular sinuses, edema of arytenoids, vocal plaque and ventricular edema and no visible enlargement of the nasopharynx, also appear standing secretion in the piriformis and vallecular sinuses, arytenoid edema, vocal plaque, and ventricular edema and appear whitish patches as well subglottic edema was found.

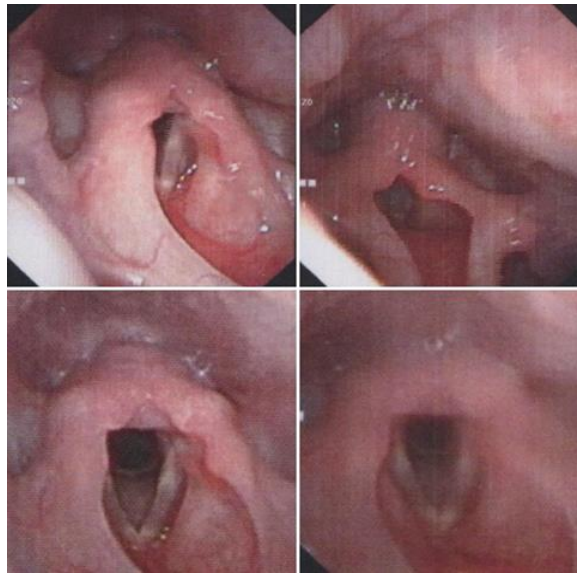


Figure 2. Patient's fiber-optic laryngoscopy showing whitish patch and subglottic edema.

The patient then treated with Omeprazole, administered twice daily, for 2 weeks, mometasone furoate nasal spray therapy 2 times daily, cetirizine, nasal irrigation with normal saline and education to modify lifestyle. Two weeks after oral Omeprazole therapy, the patient's clinical condition was

improved, No hoarseness, stridor and stertor, vesicular breath sound in both lung fields. Therapy with Omeprazole is still given for up to 2 months and continuing nasal irrigation. The IgE specific antibody was tested and did not shown to any specific allergen.

Discussion

Complaints of hoarseness, wheezing, stridor, and stertor appeared suddenly after the patient choked during mealtime. Wheezing in children has many differential diagnoses, most common is a tracheoesophageal fistula or malacia, foreign body aspiration, bronchiolitis, and gastroesophageal reflux disease (GERD)(6). The cause of infection in these patients has not been eliminated, the patient was diagnosed by a pediatrician with community-acquired pneumonia, working diagnosis was based on clinical symptoms and X-ray examination shown infiltrates in right lung field, complete blood count within normal limits. After administration of antibiotics and inhalation therapy, the patient's condition did not improve. Complaints were also felt suddenly when the patient was eating, aspiration of foreign bodies involving the upper respiratory tract was yet to be eliminated, stridor was present, that suggest the obstruction of the upper respiratory tract.

The patient has symptoms suggested caused by reflux., wheezing, stridor, cough, hoarseness was present. Refluxate from gastrointestinal or GERD may manifest several problems related to the airway, including laryngomalacia, hoarseness, vocal cord nodules, asthma even life-threatening events(7). A physician needs to know and consider what other symptoms or signs may occur in a patient with GERD.

GERD is often diagnosed by clinical signs and symptoms, where specific testing

is not needed and empiric treatment may give an improvement of the symptoms, but when airway manifestation occurs, further workup should be done to determine the underlying factors causing the symptoms, whether it caused by an anomaly of the anatomy or the manifestation of GERD.

Esophagitis, particularly eosinophilic esophagitis (EE) is described as a chronic idiopathic inflammatory disorder of esophagus that can mimic airway symptoms of GERD. The airway manifestation in EE includes wheezing, stridor, dyspnea on exertion, hoarseness, and croup. EE is a clinicopathologic diagnosis, in which symptoms and dense eosinophilia on esophageal biopsy findings lead to the diagnosis. Another testing that can be done to diagnose EE is IgE levels, blood eosinophil level, or genetic testing(7). The gold standard for diagnosing EE is made by tissue biopsy of esophagus. Clinical symptoms of esophageal dysfunction, more than 15 eosinophils in one high power field, lack of responsiveness to high dose PPI, and normal pH monitoring of distal esophagus were also included in diagnostic guidelines of EE(8). Patient clinical symptoms have improved after PPI treatment, although the patient did not undergo esophagus biopsy and esophageal pH probe monitoring, other laboratory examination within normal limit, no increased level of blood IgE and eosinophil also within normal limit. Thus, the diagnosis of EE can be eliminated in this patient.

Table 1. Symptoms and Signs that May be Associated with GERD
in Infants and Children 0 to 18 years old⁽⁹⁾

Symptoms	Signs
General	
Discomfort / Irritability	Dental erosion
Failure to Thrive	
Feeding refusal	Anemia
Dystonic neck posturing	
Gastrointestinal	
Recurrent regurgitation with/ without vomiting in the older child	Esophagitis
Heartburn / Chest pain	
Epigastric pain	Esophageal stricture
Hematemesis	
Dysphagia/ odynophagia	Barret Esophagus
Airway	
Wheezing	Apnea spells
Stridor	Asthma
Cough	Recurrent pneumonia Associated with aspiration
Hoarseness	Recurrent otitis media

In an adult, reflux screening using the scoring system can be used, namely by using a scoring system published by Belafsky et.al, Reflux Symptoms Index (RSI) and Reflux Findings Score (RFS), classification symptoms of laryngopharyngeal reflux⁽¹⁰⁾. The use of RSI and RFS scoring can be easily applied to the ORL-HNS practice as an objective parameter at a low cost and easy to use⁽¹¹⁾. Children are not a small adult and their growth are dynamic. For pediatrics, the study by Zulka proposes a new diagnostic instrument in pediatrics⁽¹²⁾. The new instrument was compromised by reflux symptoms and laryngeal signs. The condition of vocal cords abnormality or subglottic edema is obligatory. One of the reflux symptoms and 2 laryngeal signs are

needed to establish the diagnosis of LPR in a pediatric patient. LPR is diagnosed if the total score is more than 5 with any positive laryngeal sign.

The instrument consists of symptoms of frequent throat clearing, choking, annoying cough, and signs of vocal cord abnormalities and subglottic edema. Symptoms of reflux are interpreted by number, from zero to five, which increased in number also increased in severity of the complaint. The patient has frequent throat clearing symptoms in number 4, -3 for symptoms of choking and annoying cough in number 4, for laryngeal signs patient has a whitish patch (1) and presence of subglottic edema (2), based on this instrument, the patient was diagnosed with LPR.

Table 2. Reflux Symptoms and Signs Instrument for Pediatric

<u>Symptoms</u>						
Frequent throat clearing	0	1	2	3	4	5
Choking	0	-1	-2	-3	-4	-5
Annoying cough	0	1	2	3	4	5
<u>Signs</u>						
	0 = Normal					
	1 = Whitish patch					
Vocal cord abnormalities	2 = Reinke edema / nodule / granuloma					
	0 = Normal					
	2 = Present					

Chronic LPR may be associated with certain complications, especially in children. Pediatric LPR is thought to cause many respiratory and airway-related problems such as rhinosinusitis, otitis media effusion, or asthma⁽⁴⁾. There is still no gold standard for diagnosing LPR in children⁽¹¹⁾. The investigation that can be performed on LPR patients includes fiber-optic laryngoscopy and 24H pH probe monitoring, impedance working, and upper endoscopy⁽³⁾. A 24-hour double probe is placing a probe in the nose with separated two measuring endpoints, one in the proximal and second in the distal esophagus, it measures the number of reflux events (pH<4) and duration (greater than 5 minutes) also total and percentage of duration pH below 4⁽¹³⁾. This examination is difficult to assess and hard to be implemented, in this case, the patient did not undergo 24-hour pH probe monitoring. Distal pH probe monitoring examination results have a high rate of false negatives in pediatric patients with extraesophageal symptoms of GERD, affected by non-acidic

reflux commonly present in proximal esophagus and pharynx⁽³⁾. A study showed pediatric patients with GERD that underwent distal probe pH monitoring and anti-reflux therapy found distal pH studies were not predictive of positive response to anti-reflux therapy and should be avoided in this patient population. Hereby, single distal pH probe monitoring is not considered as an adequate study for a diagnostic instrument for LPR.

Examination with fiber-optic laryngoscopy or endoscopy visualization of the aerodigestive tract is useful for assessing whether LPR or GERD causing

the problem. Examination of vocal cord abnormalities and subglottic edema are useful for diagnosing LPR. Fiber-optic laryngoscopy is chosen because painless and required a short time, less than 2 minutes, and a new diagnostic instrument can also be used for diagnosing pediatrics with LPR. Zulka's reflux symptoms and signs instrument can be used for diagnosing pediatric with LPR, based on clinical symptoms and fiber-optic laryngoscopy examination results. This instrument is more feasible and more applicable in daily practice.

LPR is closely related to Otitis Media or Rhinosinusitis. The prevalence ratio of the incidence of effusion otitis media in pediatric patients with LPR was 4.5 times higher than those without LPR⁽⁴⁾. Patients with Chronic Rhinosinusitis and LPR have a correlation, both improve each other symptoms and worsen the quality of life. LPR is one of the factors that contribute to nasal mucociliary clearance damage⁽¹⁴⁾. If the nasal function was impaired, it will cause pulmonary aspiration of nasal contents, triggering nasal-bronchial reflex, and increased absorption of inflammatory mediators that may be responsible for lower airway dysfunction⁽¹⁵⁾. Neural communications are linking upper dan lower airways, the trigeminal nerve that responsible for an afferent sensory impulse from the nose, from nasopharynx via glossopharyngeal nerve and efferent impulses to the bronchi via vagal nerve mediate bronchoconstriction and contribute to nasobronchial reflex that responsible for interactions between upper and lower airways

Nasal mucociliary clearance (NMC) is one of the innate defense mechanisms of the nasal and paranasal sinuses. The mucus, which is secreted by the upper respiratory tract, traps particulates, allergens, and pathogens which will be transferred to the pharynx by the cilia and will be swallowed⁽¹⁵⁾. Nasal mucociliary clearance (NMC) damage can predispose to infections of the nose, paranasal sinuses, and respiratory tract. Disorders of the mucociliary clearance time can occur in patients with LPR, refluxate in the form of hydrochloric acid and pepsin directly affect mucociliary function, the vagus nerve-mediated autoimmune response results in

nasal mucosal edema which affects cilia motility and Helicobacter pylori which are contained in refluxate damage mucosal lining directly⁽¹⁶⁾. Decreased laryngopharyngeal receptor sensitivity may result from refluxate, which could potentially result in an increased risk of aspiration that may lead to aspiration pneumonia⁽¹⁷⁾.

Treatment with nasal irrigation as an adjunct for common cold/rhinosinusitis, chronic sinusitis, allergic rhinitis, and after nasal surgery. Nasal irrigation moisturizes nasal mucous membranes, reduces crusting, and improves mucus retention from the nose and sinuses⁽¹⁷⁾. Administration of low-salts and isotonic solution associated with a significant reduction in microbial antigen concentration. In general, this therapy is cheap and easy to do even for children. Intranasal steroid administration, in this case, mometasone furoate. The use of mometasone furoate as therapy and/or prophylaxis of nasal symptoms of allergic rhinitis and perennial allergic rhinitis has become the standard treatment with a level of evidence Ia⁽¹⁸⁾. Treatment with mometasone furoate in the pediatric population has also shown excellent efficacy for the management of adenoid hypertrophy and effusion otitis media, despite concomitant atopy. In pediatric patients suffering from allergic rhinitis, it shows better clinical improvement, better efficacy, safer and lower total cost of care. Based on the history and physical examination, that the risk of allergies cannot be ruled out, so the cause and management of allergies that triggered allergies, this treatment was given.

Successful anti-reflux drug treatment can also be used as a diagnostic tool with improved clinical symptoms after therapy. In the pediatric population, this still requires further study. Empirically, therapy using proton pump inhibitor (PPI) can be given to patients with LPR. Omeprazole and Lansoprazole can be used. Administration of Omeprazole at a dose of 0.5 -2 mg / Kg Body Weight per day is divided into two doses and in twice the administration, morning, and evening 30 minutes before meals. The therapy can be given up to 2-3 months. If after treatment symptoms did not improve, further re-examination is necessary. Prokinetic agents are not recommended, especially with

metoclopramide and cisapride, due to the dangerous side effect of the extrapyramidal syndrome.

Ideally, for comprehensive management patients with LPR, a team of speech /swallowing therapists, radiologists, gastroenterologists, and otolaryngologists should work together to evaluate and treat patients with LPR⁽³⁾. The most important thing to note is lifestyle modification. Taking a good diet is as effective as PPI therapy. In general, alkaline, protein, low-fat and low-acid foods are quite effective because they are easily digested and can reduce transient relaxation of the esophageal sphincter associated with LPR episode. Caffeine, mint, and citrus diet should be avoided. The patient also needs to avoid large meals before activity and eating shortly before bedtime⁽²⁾. In infants or children, especially those who are still breastfeeding, changes in position can reduce reflux up to 80% and reduce regurgitation rates by about 65%(3). Other conservative management that can be applied are elevation of the head of the bed, avoidance of caffeine, mint, and citrus,

avoidance of large meals before activity, and avoidance of meals shortly before sleeping.

Conclusion

To diagnose pediatric LPR is often a challenge for physicians. Children are not a small adult and their growth are dynamic. The physician needs to know and understand the correlation and manifestation that may occur caused by LPR that affects the upper and lower airway. Pediatric LPR may manifest many atypical symptoms that result in difficulties in diagnosing and treating patients with LPR. The new instrument can be used to diagnose pediatric LPR, it is feasible and applicable in daily practice. Laryngopharyngeal reflux needs to be listed as a differential diagnosis in pediatric with cough, stridor, or hoarseness. By knowing and understand the manifestation that may occur, physicians may be able to diagnose pediatric LPR properly and provide comprehensive management.

References:

1. Swain SK, Choudhury J. Experience with the management of pediatric laryngopharyngeal reflux in an Indian teaching hospital. *J Clin Sci.* 2020;17(3):61–5.
2. Ricket SM, B.Zur K. Disorders of the Pediatric Voice. In: *Pediatric Otolaryngology Principles and Practice Pathways.* Thieme Medical Publisher; 2012. p. 690.
3. Sowa L, Schimdt H, Gerber ME. Laryngopharyngeal Reflux. In: *Multidisciplinary Management of Pediatric Voice and Swallowing Disorders.* Springer Nature Switzerland; 2020. p. 227–38.
4. Karyanta M, Satrowiyoto S, Wulandari DP. Prevalence Ratio of Otitis Media with Effusion in Laryngopharyngeal Reflux. *Int J Otolaryngol.* 2019;2019(November 2016):1–3.
5. Kopka M, Matecka M, Stelmach I. Chronic cough as a symptom of laryngopharyngeal reflux — Two case reports. *Adv Respir Med.* 2016;85(1):29–32.
6. Al-Shamrani A, Bagais K, Alenazi A, Alqwaiee M, Al-Harbi AS. Wheezing in children: Approaches to diagnosis and management. *Int J Pediatr Adolesc Med [Internet].* 2019;6(2):68–73. Available from: <https://doi.org/10.1016/j.ijpam.2019.02.003>
7. Hartnick CJ, Maturo SC. Airway Manifestation of Pediatric Gastrophageal Reflux Disease. In: *Pediatric Otolaryngology Principles and Practice Pathways.* Thieme Medical Publisher; 2012. p. 600–9.
8. Furuta GT, Liacouras CA, Collins MH, Gupta SK, Justinich C, Putnam PE, et al. Eosinophilic Esophagitis in Children and Adults: A Systematic Review and Consensus Recommendations for Diagnosis and Treatment. Sponsored by the American Gastroenterological Association (AGA) Institute and North American Society of Pediatric Gastroenterol. *Gastroenterology.* 2007;133(4):1342–63.
9. Rosen R, Vandenplas Y, Singendonk M, Cabana M, Dilorenzo C, Gottrand F, et al. Pediatric Gastroesophageal Reflux Clinical Practice Guidelines: Joint Recommendations of the North American Society for Pediatric Gastroenterology, Hepatology, and Nutrition and the European Society for Pediatric Gastroenterology, Hepatology, and Nutritio. Vol. 66, *Journal of Pediatric Gastroenterology and Nutrition.* 2018. 516–554 p.
10. Belafsky PC, Postma GN, Koufman JA. Laryngopharyngeal reflux symptoms improve before changes in physical findings. *Laryngoscope.* 2001;111(6):979–81.
11. Ugras MK, Dogan M, Pata DYS, Ozkan F. Can the Reflux Finding Score and Reflux Symptom Index Be Used to Evaluate the Severity of Esophagitis in Children? *J Voice [Internet].* 2019; Available from: <https://doi.org/10.1016/j.jvoice.2019.07.023>