

Case Report : Caecal Endometriosis is Causing Acute Small Bowel Obstruction

Freda S.Halim¹

¹Departement of Surgery Faculty of Medicine, University of Pelita Harapan
Siloam Hospital Lippo Village

Citation : Halim FS. Case Report : Caecal Endometriosis is Causing Acute Small Bowel Obstruction
Medicus. 2019 February; 7(5):154–161
Keywords : Endometriosis, Caecum, Bowel Obstruction
***Correspondance** : Freda S. Halim, Surgery Department, Siloam Hospital Lippo Village Faculty of Medicine, University of Pelita Harapan. .
E-mail : Freda.halim@uph.edu
Online First : June 2020

Abstract

Introduction: Endometriosis in bowel is rare condition, about 12% of endometriosis cases. Most of bowel endometriosis rising in the rectosigmoid (90% of bowel endometriosis). Incidence of caecal endometriosis is very low (<5% of bowel endometriosis) and almost never causing acute small bowel obstruction(0.1-0.7%). The aim of this paper is to show that although bowel obstruction caused by caecal endometriosis

is difficult to diagnose as it is rare, and may require laparotomy to make definite diagnosis, but it should be considered in infertile female patient.

Case: 37 years old woman infertile woman with intestinal obstruction with pre-operative diagnosis total acute small bowel obstruction caused by right colonic mass, with sepsis as the complication. Before the acute small bowel obstruction she complained of chronic right lower quadrant pain with chronic constipation alternate with chronic diarrhea, symptoms that happened both in bowel endometriosis and colorectal malignancy. She also complained of chronic pelvic pain and dysmenorrhea. She has been married for 10 years with no child. The patient was never diagnosed with endometriosis and never seek medical attention for the infertility and the chronic pelvic pain. The patient underwent Abdominal CT Scan, with result: massive small bowel obstruction, and caecal mass that causing acute small bowel obstruction. Diagnosis of Acute small bowel obstruction due to right colonic mass was made and emergency exploratory laparotomy was performed the patient.

Methods: During the laparotomy, mass at caecum and ileocaecal that causing massive small bowel obstruction was found and standard right hemicolectomy and temporary mucousfistula ileostomy was performed.

Result: The patient recovered well, discharged on 7th day post op. The pathology examination showed ectopic endometriosis lesions in caecum and ileocaecal valve. The histopathology also confirmed with the immunohistochemistry, in which positive ER, PR, CD 10 and CD7 was found the ileocaecal and caecal mass. In the second operation, reanastomosis of the ileum was done 3 months after the first operation. The chronic pelvic pain is decreasing dramatically after the first and second operation.

Conclusion: Although bowel obstruction caused by caecal endometriosis is an extremely rare cause of intestinal obstruction but it should be considered as a cause in infertile female patient to reduce morbidity and mortality, to reduce stoma creation and to promote resection completeness.

Case Illustration

37 years old patient came to ER with chief complaint of difficulty to defecate and pass gas within the last 3 days, accompanied with distended and colic intermittent abdominal pain. Patient complained of chronic intermittent diarrhea with blood and chronic pelvic pain. The patient has history of infertility (10 years of marriage without child) with dysmenorrhea. The patient has never seek any medical attention for the gynecological problem. At arrival : BP 120/90mmHg, HR 110x/minute, RR 24x/minute, Temp 37 Celcius degree. Laboratory finding : Hb 12.5gr/dL, WBC : 24.000/mm³, Ht 36%, Platelet 305.000/mm³. Other lab finding is within normal limit.

Radiologic Finding

Abdominal x-ray confirmed that patient has obstructive ileus with step ladder pattern sign with high level obstruction/small bowel obstruction(Gambar 1-3). Abdominal CT Scan with IV contrast was done to seek the cause of obstruction, with conclusion the cause is mass in the right colon(figure 4 and 5). No other cause of obstruction and other abnormalities found in the abdominal CT Scan.

Surgical Evaluation and Specific Finding

Patient underwent emergency exploratory laparotomy in which we found massive dilatation of small bowel caused by palpated intraluminal mass in caecal region, with collapsed large bowel(figure 6). Standard right hemicolectomy(removeal of terminal ileum until proximal transverse colon) was done and ileostomy mucousfistula was constructed in this patient. Patient recovered well within 1 week in the hospital and then she was discharged without complication.

Histopathologic Finding

After operation, specimen was opened and irregular mass in caecum and ileocaecal valve (Figure 7) with appropriate microscopic finding, with positive endometrial tissue in bowel (Figure 8). This histopathologic finding was proven with immunohistochemistry staining of Estrogen Receptor(ER) and Progesteron Receptor(PR) also cytokeratin (CK) 7 and CK 10. Endometrial glands are stained by ER, PR and CK7 staining, bowel epithelial was stained with CK 10(figure 9).

Post Operative Follow Up

Patient has recovered well, and discharged 1 week after the operation. In the 3rd month, the patient was done ileal reanastomosis and chronic pelvic pain is reduced dramatically in this patient.

Discussion

Endometriosis is gynecological condition in which the functional endometrium is found outside the uterus.¹ Endometriosis is found in 6-10% women in reproductive age, and only 50% of the endometriosis patient shows pelvic pain, abnormal period, and infertility caused by the endometriosis.² Frequent affected location are pelvic peritoneum, ovarium and rectovaginal septum.² Infrequent location of the endometriosis are pleura, pericardium, small bowel and large bowel, and other tissues.²

Bowel endometriosis are the most frequent site of endometrial location outside pelvis, about 12% of the extrapelvic case.^{3,4} And the lesion in the bowel causing bowel obstruction is very rare only 0.1 until 0.7%, and most of them are found in rectosigmoid and rarely found in caecum.⁵

Etiology of endometriosis are not truly understood. Usually the retrograde menstruation is commonly mentioned but not all women with retrograde menstruation has endometriosis.² Another theory mentioned vascular dissemination, colonic metaplasia and autoimmune disease⁵ Endometriosis act like endometrial tissue in uterine and responded to ovarian hormone although attached to other organ. Even endometriosis could implanted and formed cyst or nodule(endometrioma).² In the attached location, endometriosis could cause bleeding, fibrosis and pain(as in this patient).⁵

As mentioned above, bowel endometriosis rarely causing obstruction(0.1-0.7% of all cases). This is because bowel endometriosis usually in the submucous layer of the bowel only, and not infiltrating deeply to the bowel wall.⁵ In general the patient complains of non-specific symptoms like pain, nausea, vomiting, bloated abdomen, diarrhea and constipation and all these symptoms usually cyclical(proliferation of endometrial tissue is depend on ovarian hormones).^{2,6}

Very rarely endometriosis proliferate, causing fibrosis and strictures of the bowel and causing bowel obstruction.^{3,4,5}

Diagnosis of bowel endometriosis is not easy to make, because a lot of GIT symptoms are alike, and in the small lesions it is not specific. In the large lesion, the symptoms is like other bowel tumor, and the abdominal CT Scan usually large lesion will formed thickening of the bowel wall(like any other bowel tumor).⁹ Transvaginal USG and Pelvic MRI could give clear picture to see any endometrioma but it is hard to see the real bowel adhesion caused by the endometriosis itself.² Endoscopic evaluation usually don't show any pathologic lesion unless the lesion is arising in the bowel mucosa and could be biopsied by endoscopy.⁸ The gold standard of diagnosis is laparoscopy(direct visualization) and biopsy via laparoscopy, which could give direct view of pelvis and bowel resection could be done if needed.⁸

In this patient, endometriosis is not considered as cause of obstruction preoperatively because all of the sign and symptoms could be find in the obstructed bowel due to right colonic tumor. Endoscopy is not done in this patient because she already in obstructed bowel condition, and abdominal CT Scan already give clear explanation of obstruction and the cause of it (right colonic mass). Also laparoscopy could not be done because she is in total bowel obstruction, with very distended abdomen. The surgeon decided for emergency exploratory laparotomy in which caecal mass is found. In the

histopathology and immunohistochemistry staining was found that the mass is an endometrioma.

Empiric therapy could be given for dysmenorrhea and chronic pelvic pain in patient suspected endometriosis. The first line therapy usually NSAID combined with cyclical oral continuous oral contraception.^{9,10} Another option is including gonadotropin releasing hormone (GnRH) agonist and aromatase inhibitors.^{2,6} These medications works by suppressed the inflammation, suppressed and disturbing the ovarial hormones production causing hypoestrogenic, endometrial atrophy and causing oligomenorrhea and amenorrhea.^{2,11} Surgery option including resection and adhesiolysis is offered in the deep infiltrating endometriosis (DIE). In the patient with DIE and/or the medicine could not work for endometriosis, surgery is an option to be considered.^{2,6,12} The success of operation depends on the completeness of resection, so the success is very depended on the pre-operative diagnosis. Pre-operative diagnosis made before obstruction could also reduce morbidity and mortality of the patient, and also reduce stoma creation like in this patient.¹³

Conclusion

Although bowel obstruction caused by caecal endometriosis is an extremely rare cause of intestinal obstruction but it should be considered as a cause in infertile female patient to reduce morbidity and mortality, to reduce stoma creation and to promote resection completeness.

References

1. Montalto M., Santoro L., D'Onofrio F., Gallo A., Campo S., Campo V. Endometriosis, need for a multidisciplinary clinical setting: the internist's point of view. *Intern. Emerg. Med.* 2010;5(6):463–467.
2. Giudice L.C. Clinical practice. Endometriosis. *N. Engl. J. Med.* 2010;362(25):2389–2398.
3. Macafee C.H., Greer H.L. Intestinal endometriosis. A report of 29 cases and a survey of the literature. *J. Obstet. Gynaecol. Br. Emp.* 2016;196067:539–555.
4. Ribeiro P.A., Rodrigues F.C., Kehdi I.P., Rossini L., Abdalla H.S., Donadio N. Laparoscopic resection of intestinal endometriosis: a 5-year experience. *J. Minim. Invasive Gynecol.* 2006;13(5):442–446.
5. Katsikogiannis N., Tsaroucha A., Dimakis K., Sivridis E., Simopoulos C. Rectal endometriosis causing colonic obstruction and concurrent endometriosis of the appendix: a case report. *J. Med. Case Rep.* 2011;5:320.
6. Al-Talib A., Tulandi T. Intestinal endometriosis. *Gynaecol. Surg.* 2010;7:61–62.

7. Ribeiro H.S., Ribeiro P.A., Rossini L., Rodrigues F.C., Donadio N., Aoki T. Double-contrast barium enema and transrectal endoscopic ultrasonography in the diagnosis of intestinal deeply infiltrating endometriosis. *J. Minim. Invasive Gynecol.* 2008;15(3):315–320.
8. Pramateftakis M.G., Psomas S., Kanellos D., Vrakas G., Roidos G., Makrantonakis A. Large bowel obstruction due to endometriosis. *Tech. Coloproctol.* 2010;14(Suppl. 1):S87–9.
9. Harada T., Momoeda M., Taketani Y., Hoshiai H., Terakawa N. Low-dose oral contraceptive pill for dysmenorrhea associated with endometriosis: a placebo-controlled, double-blind, randomized trial. *Fertil. Steril.* 2008;90(5):1583–1588
10. Vercellini P., Frontino G., De Giorgi O., Pietropaolo G., Pasin R., Crosignani P.G. Continuous use of an oral contraceptive for endometriosis-associated recurrent dysmenorrhea that does not respond to a cyclic pill regimen. *Fertil. Steril.* 2003;80(3):560–563.
11. Miller E.S., Barnett R.M., Williams R.B. Sigmoid endometriotic stricture treated with endoscopic balloon dilatation: case report and literature review. *Md. Med. J.* 1990;39(12):1081–1084.
12. Whelton C., Bhowmick A. Acute endometrial bowel obstruction-a rare indication for colonic stenting. *Int. J. Surg. Case Rep.* 2013;4(2):160–163.
13. Arafat S., Alsabek M.B., Almousa F., Kubtan M.A. Rare manifestation of endometriosis causing complete recto-sigmoid obstruction: a case report. *Int. J. Surg. Case Rep.* 2016;26:30–33.

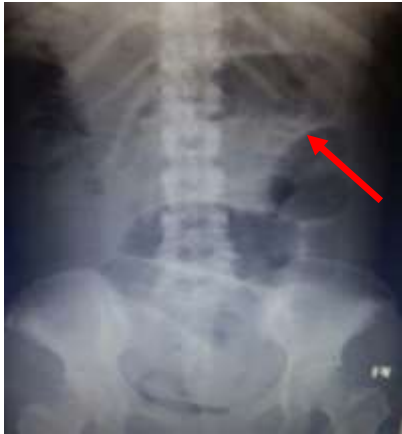

Figure 1. Supine abdominal x-ray shows small bowel dilatation with herring-bone sign

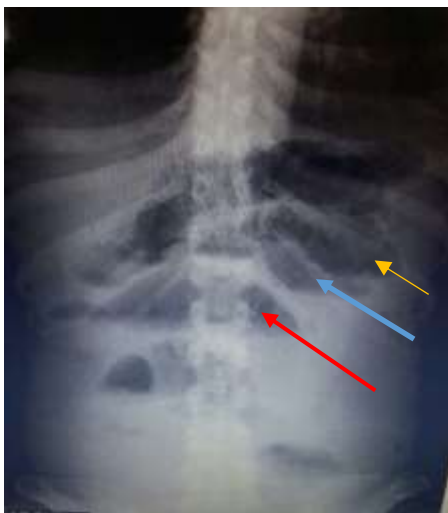

Figure 2. Erect abdominal x-ray shows classic step ladder pattern, a pathognomonic sign for acute bowel obstruction

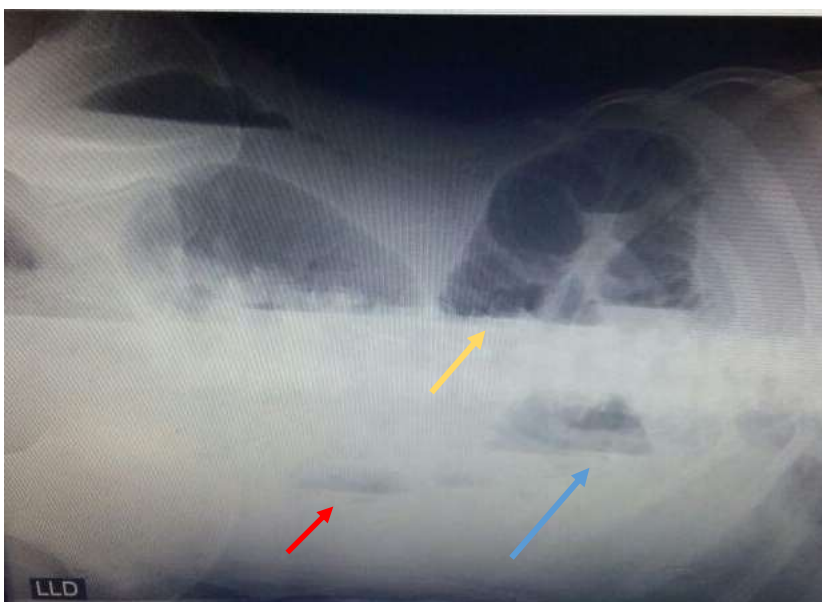


Figure 3. X-ray of Left Lateral Decubitus shows multiple air fluid level and step ladder pattern

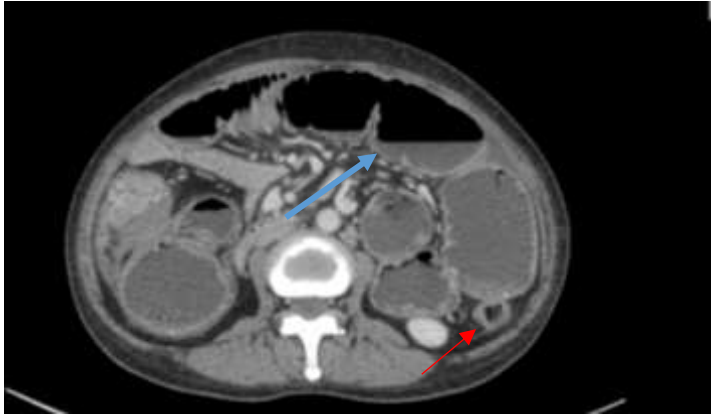


Figure 4. Abdominal CT Scan in saggital plane shows massive dilatation of small bowel (blue arrow) with collapsed large bowel (red arrow)

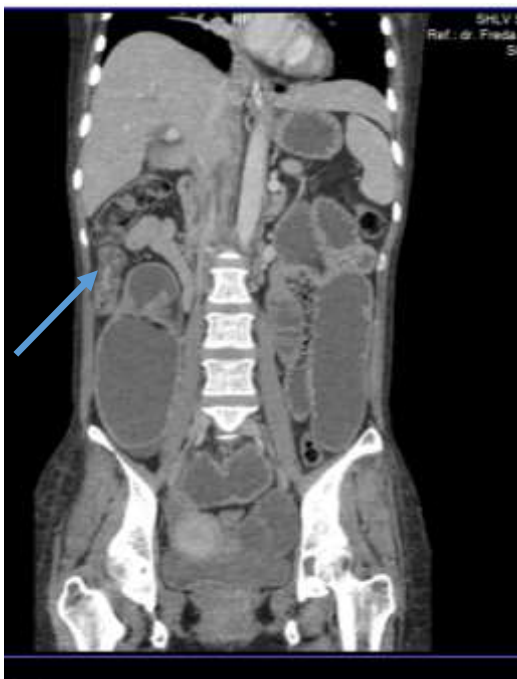

Figure 5. Abdominal CT with IV contrast in coronal section, shows massive dilatation of small bowel with collapsed right large bowel (blue arrow)

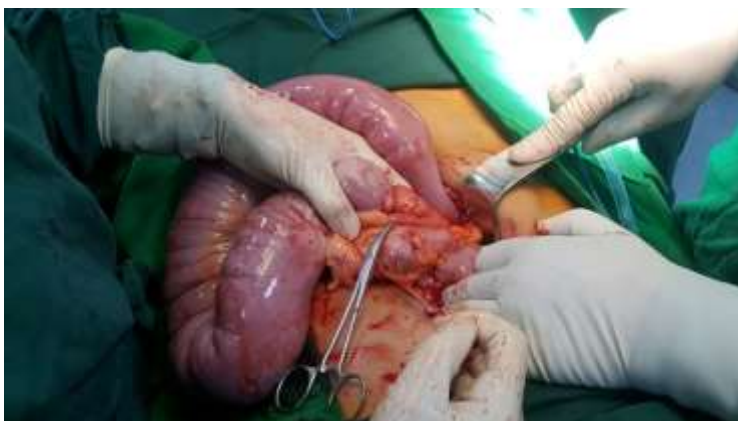

Figure 6. Intraoperative findings indicate massive small bowel obstruction with a mass in the Caecum (appointed with clamps)

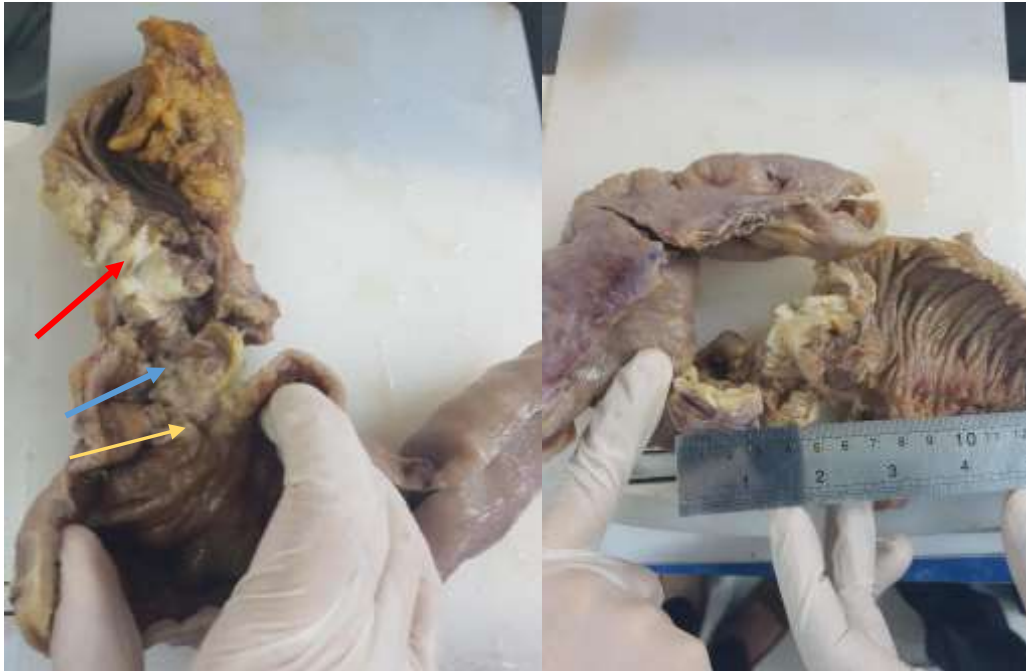

Figure 7. Macroscopic finding of the tissue shows infiltrative endometriosis in caecum(red arrow) and ileocaecal valve (blue and yellow arrow)

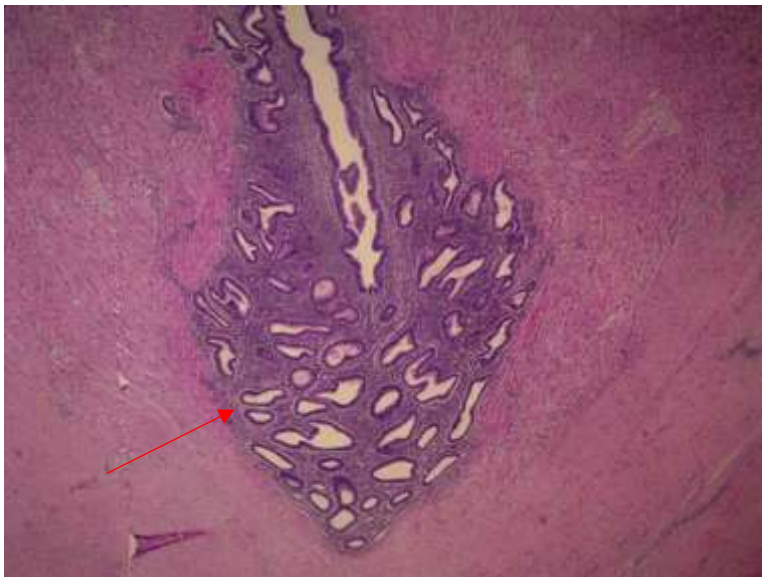

Figure 8. Histopathologic finding shows invasive endometriosis to normal caecal tissue

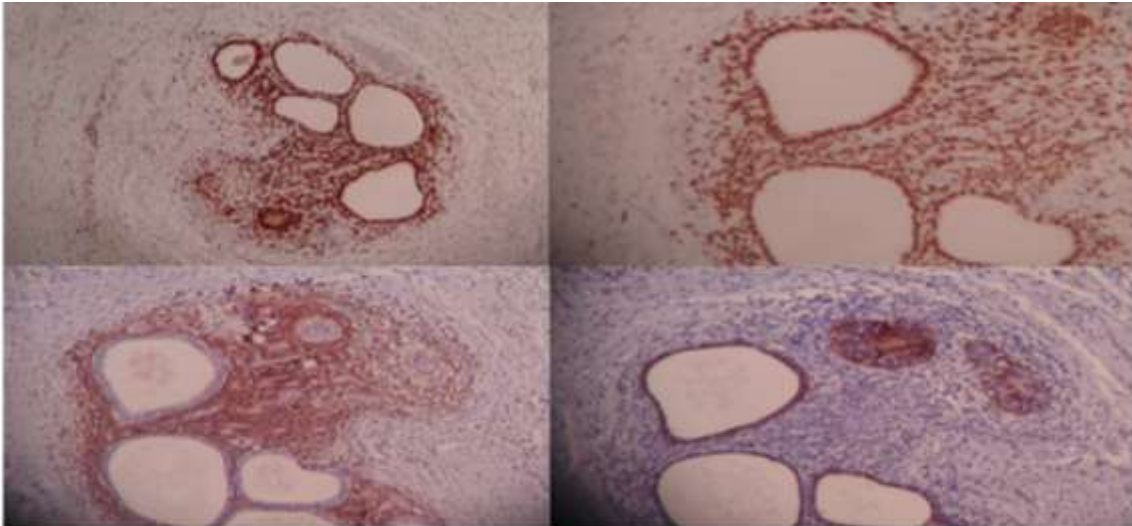


Figure 9. Immunohistochemistry staining shows positive result for ER, PR, CK 7 confirmed of endometrial tissue and CK 10 that confirmed bowel epithelial