

The Controversy of Hydatidiform Mole Treatment In Women age ≥ 40 year-old

Gabriella Fara¹, Julita D.L. Nainggolan²

¹ Faculty of Medicine, University of Pelita Harapan

² Department of Obstetrics and gynaecology, Faculty of Medicine, University of Pelita Harapan

Abstract

Background: Hydatidiform mole or commonly known as molar pregnancy is one of the gestational trophoblastic disease (GTD) caused by an abnormal trophoblast proliferation. About 50% of gestational trophoblast neoplasm (GTN) arises from molar pregnancy. Higher risk of GTN was found in older patient, especially women age ≥ 40 years old. Management of hydatidiform mole is often faced come challenges, especially in developing country like Indonesia. Although, suction curettage is the most recommended treatment for the evacuation of molar pregnancy, hysterectomy is considerable for women who have completed childbirth and do not wish to preserve their fertility.

Case: Here we present case of 48 years old women with hydatidiform mole. Considering the age of the patient and the completion of her childbearing, we decided to do a laparotomy total abdominal hysterectomy for the evacuation of the mole instead of suction curettage. Turned out that this patient had an invasive mole, one of the types of gestational trophoblastic neoplasia.

Conclusion: Although suction curettage is the most frequent technique for molar evacuation, hysterectomy is a reasonable option as primary treatment to be performed in older patients and for those who do not wish to preserve their fertility. The other important points such as socio-economic status, education level, and geographical issues should be considered also on managing older patients with hydatidiform mole in developing countries.

Keywords : *hydatidiform mole treatment, hysterectomy, suction curettage, gestational trophoblast neoplasm (GTN), gestational trophoblastic disease (GTD)*

pISSN: 1978-3094 • Medicinus. 2017;6(2):43-9

Background

Hydatidiform Mole or commonly known as molar pregnancy is one of the gestational trophoblastic disease caused by an abnormal trophoblast proliferation.¹ It is a rare but important pregnancy-related disease with an incidence of 1,1 to 1,57 in 1000 pregnancies in United States, Australia, New Zealand, and Europe, whereas in South East Asia reached 2 cases per 1000 pregnancies.² The highest incidence of molar pregnancy was found in women with a previous history of molar pregnancy and those at extreme age.^{2,3} There is 1.3 fold increase of incidence in teenager (<21 years old) and 10 fold increase in women age ≥ 40 years old.³ About 50% of gestational trophoblast neoplasm (GTN) arises from molar pregnancy. Gestational trophoblast neoplasm occurs in 1 per 40.000 pregnancies in Europe and America, and 9,2 per 40.000 pregnancies in South East Asia.⁴ The treatment option is important in order to evacuate the molar tissue, also to determine the patient's fertility. Suction curettage is the recommended treatment for the evacuation of molar pregnancy.⁵

Another author suggests hysterectomy as treatment for women who have completed childbirth and do not wish to preserve their fertility.⁶ Management of hydatidiform mole is often faced come challenges, especially in developing country like Indonesia. We present a case of 48 years old woman, G6P2A3, with hydatidiform mole associated with thyrotoxicosis which was treated with total abdominal hysterectomy.

Case Report

A 48 years old woman G6P2A3 on her 11th week age of gestation presented with a chief complaint of vaginal bleeding accompanied with blood clots since few hours prior to consult. She had a history of abdominal pain, nausea, vomiting, and loss of appetite. She also felt sweaty and palpitations without any provocation.

This patient has a history of chronic uncontrolled hypertension. She only had two times prenatal check-up at a midwife and no ultrasound had done. On physical examination she had tachycardia (112 BPM), high blood pressure (180/110 mmHg), the respiration rate was 18 breaths per minute, and the temperature was 36,5°C. There were no exophthalmos and

Corresponding Author:

Julita D. L. Nainggolan 

Faculty of Medicine Universitas Pelita Harapan
Jl. Boulevard Jend.Sudirman, Lippo Karawaci, Tangerang,
Indonesia. Tel: +62-21-54210130; Fax: +62-21-54210133;
Email: julita.nainggolan@uph.edu

enlargement of thyroid gland. Cardiovascular examination revealed sinus tachycardia without murmurs or gallop. The abdomen was soft, no tenderness with palpated enlarged uterus as 16 weeks size.

Obstetrics and gynecology examination revealed a normal vulva and vagina. On speculum examination, the vaginal canal seemed smooth, the cervix was also smooth and there was minimal blood from the ostium of cervix, there was no mass seen. From bimanual

examination, the uterus was palpated enlarged in size equals to 16th week of pregnancy and no tenderness or adnexal mass was palpated.

The ultrasonography examination of the uterus showed an enlarged uterus filled with 11x10x6 cm echogenic and anechoic mass with a *snow storm* appearance; there was no mass on the adnexa or free fluid on the cul de sac (rectouterine pouch); and the bilateral ovarium were normal.

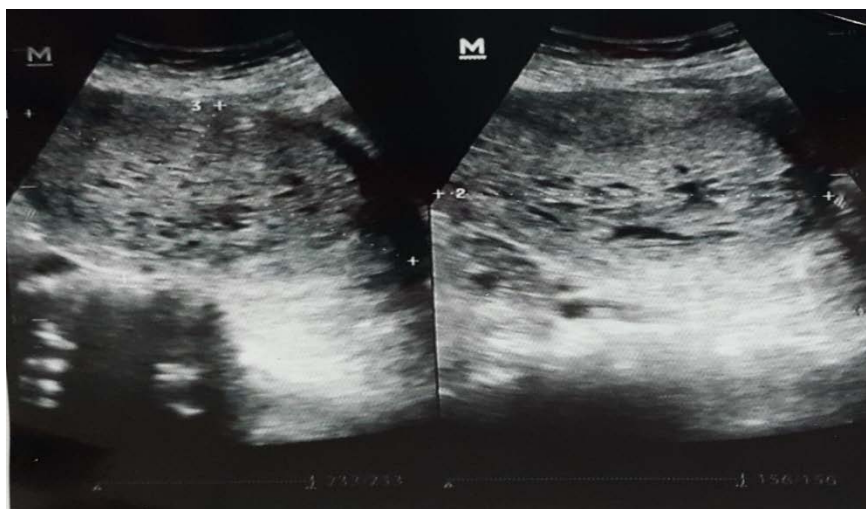


Figure 1. Ultrasonography examination shows a “snow storm” appearance

The laboratory examination showed a microcytic hypochromic anemia (Hb 10,8 and normal level of MCV, MCH, MCHC), decreased level of thyrotrophin/TSH (0,007 mIU/mL), also increased level of free T4 (2,51 ng/dL) and beta-human chorionic gonadotropin level (1.534.319 mIU/mL). The chest x-ray examination was normal. The echocardiography showed sinus tachycardia. She was diagnosed with hydatidiform mole with thyrotoxicosis. The patient was referred to internal medicine to manage the thyrotoxicosis condition. Considering the age of the patient and the completion of her childbearing as well

as the socioeconomic status of this patient, we decided to do a laparotomy total abdominal hysterectomy for the evacuation of the mole instead of doing suction curettage. We noted a mass at the fundal area of the uterus measured 1,5 x 1 cm during the surgery, that changed our initial diagnosis of hydatidiform mole into an invasive mole. Histopathology examination confirmed the diagnosis of invasive mole. The postoperative course was uneventful, patient was discharged on the second day post surgery in good condition and planned to refer to the oncologist for further evaluation and management.

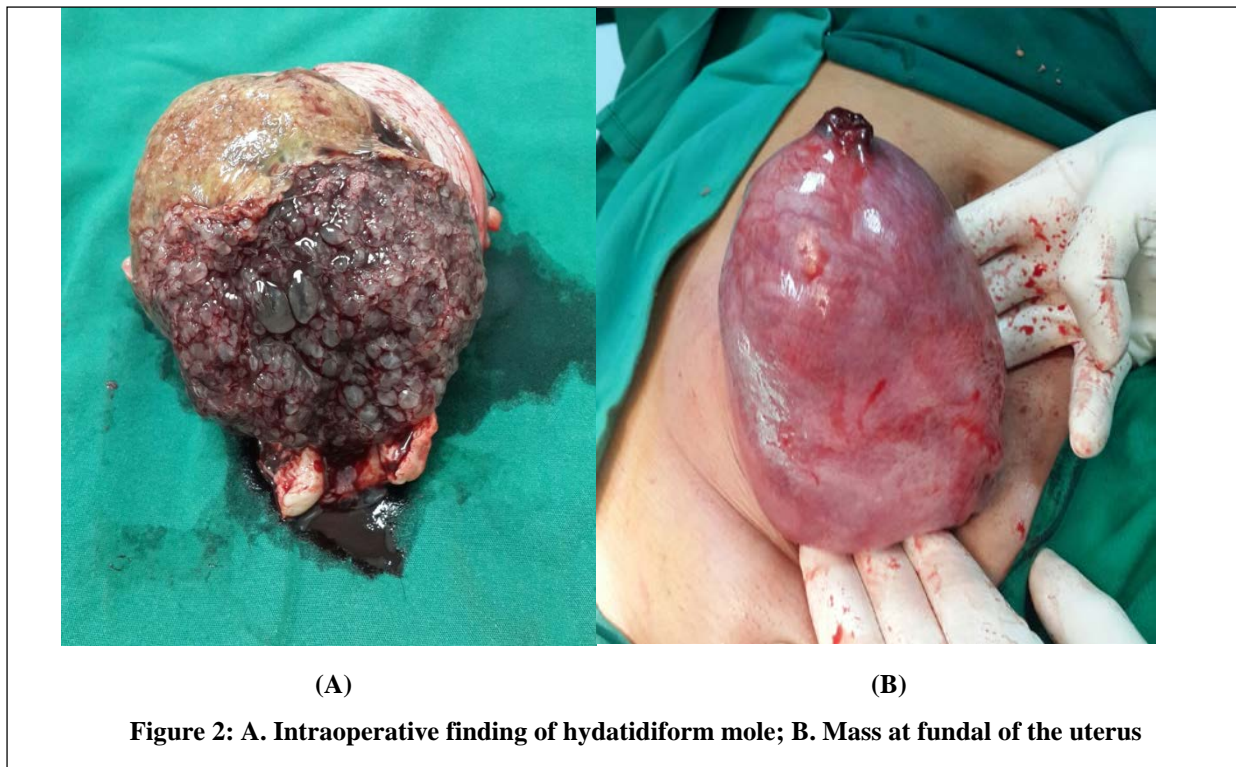


Figure 2: A. Intraoperative finding of hydatidiform mole; B. Mass at fundal of the uterus

Discussion

Hydatidiform Mole or commonly known as molar pregnancy is one of the gestational trophoblastic disease caused by an abnormal trophoblast proliferation.¹ Gestational trophoblastic disease (GTD) consist of hydatidiform mole (partial, complete) and non-molar trophoblast neoplasm (invasive mole, choriocarcinoma, placental site trophoblastic tumor, epitheloid trophoblastic tumor).⁷ Hydatidiform mole usually arises from chromosomal abnormalities during fertilization. Complete mole has a diploid chromosome (46,XX), caused by an absent or inactivated maternal chromosome when it was fertilized by paternal chromosome.⁷ Partial mole have triploid karyotype (69,XXX; 69,XXY; or 69,XYY) which consists of two paternal haploid chromosomes and one maternal haploid chromosome.⁷ Invasive mole (chorioadenoma destruens) mostly arise from a complete mole, characterized by molar tissue invasion of myometrium.³

Patient with hydatidiform mole commonly presents with vaginal bleeding or passing blot clot (molar tissue), hyperemesis, signs of anemia, enlargement of uterus more than the actual gestational age.⁸

Hydatidiform mole may be associated with thyrotoxicosis caused by an excessive hCG levels.⁷ Thus, the patient may also experience thyrotoxicosis symptoms such as palpitation, easily sweaty, increased heart rate and blood pressure.⁷ In molar pregnancy, β -hCG level can increase beyond the level appropriate to the gestational age.⁸ β -hCG level in normal pregnancy does not exceed 60,000 mIU/mL, but in molar pregnancy it exceed 100,000 mIU/mL or even millions in complete mole.⁹

From ultrasound examination, complete mole can be seen on second trimester as intrauterine heterogeneous mass ("snowstorm" appearance) without fetal development, and with theca-lutein ovarian cyst.¹⁰ Partial mole appear as a placenta that has a thickened multi-cystic lesion and contain fetus.^{2,7} Whereas invasive mole appear as heterogenous, hyperechoic, solid mass with cystic vascular spaces, located within the myometrium. Another modalities to assess suspected invasive mole are colour Doppler (to asses prominent blood flow signals as angiogenesis and neovascularization) and Doppler velocimetric (low-impedance arterial flow and high velocity).¹¹ The pathological anatomy examination is to confirm the diagnosis of GTD.⁷

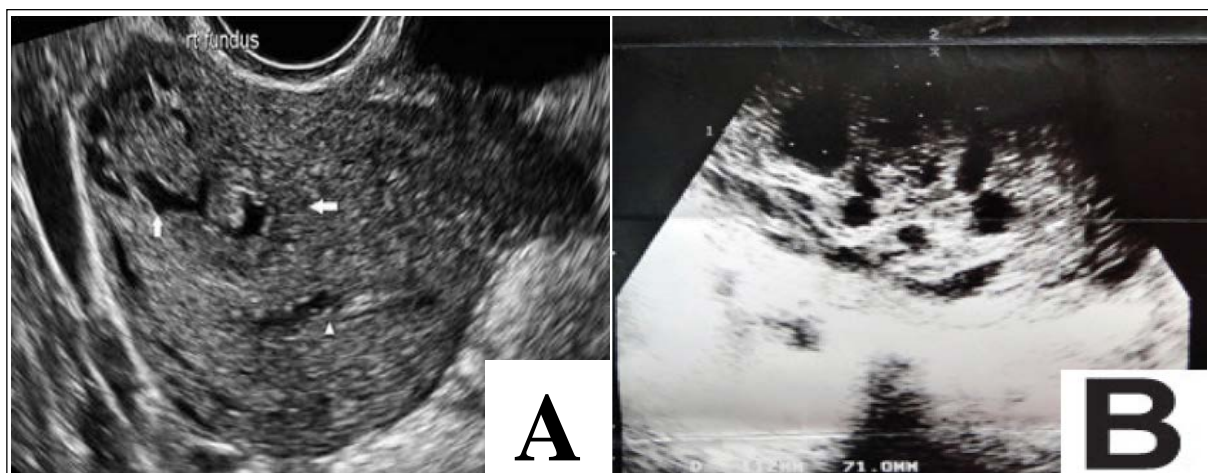


Figure 3 : A. Transvaginal ultrasound of Invasive mole : ill-defined heterogenous hyperechoic solid lesion with cystic areas seen in myometrium, right fundal region of the uterus, away from myometrium;¹²
 B. Pelvic ultrasound of complete hydatidiform mole : vesicle pattern of multiple echoes, hypoechoic lesion within placenta (*snowstorm appearance*)¹³

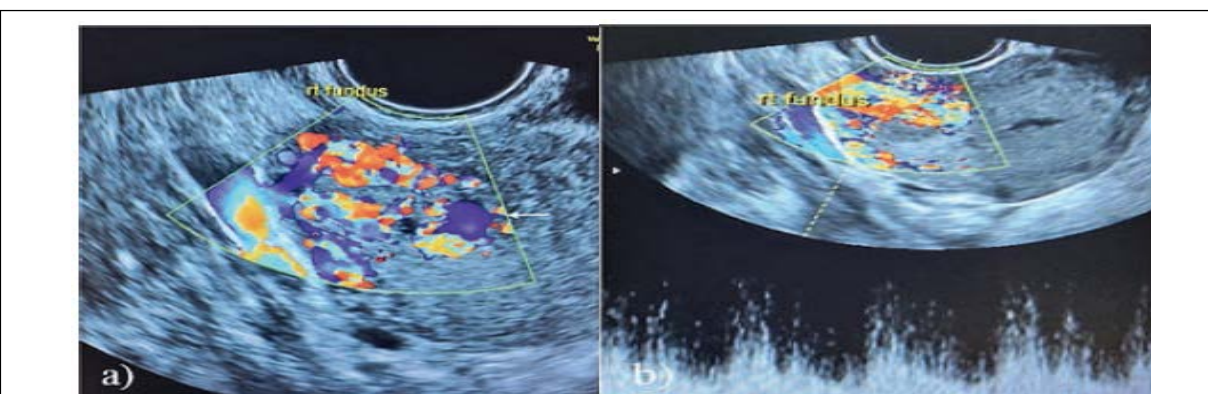


Figure 4 : A. Colour Doppler showed prominent blood flow within lesion suggestive of neovascularization.
 B. Pulsed Doppler showed low vascular impedance arterial blood flow¹²

In this case report, the patient experienced most of hydatidiform mole's symptoms and her ultrasonography examination showed a "snowstorm" appearance, there were no features of invasive mole. She was not examined by colour Doppler or Doppler velocimetry due to limited resources.

There are several options available for the treatment of GTD includes suction curettage, hysterectomy, and chemotherapy.¹⁴ According to the Society of Obstetricians and Gynaecologists of Canada (SOGC) Guidelines, suction curettage is the preferred method of. Although hysterectomy is not recommended as routine practice, it is a reasonable option for patient who do not wish to preserve their fertility or has completed childbearing and wants a surgical sterilization.^{14,15,18-20} Hysterectomy can also be performed in cases which the repair of uterine rupture is not

mola hydatidosa evacuation regardless of uterine size, especially in patients who desire to preserve fertility.^{15,16} On the other hand, curettage can increase the risk of uterine perforation (especially when sharp curettage is being used), hemorrhage, and pulmonary emboli. These complications rarely occur in cases where the uterine size is below a 16 week pregnancy.¹⁷ A routine repeated evacuation of hydatidiform mole is not warranted, because there were no clear indications and it does not eliminate the risk of gestational trophoblast neoplasm.^{16,18}

possible or when the hemorrhage threatens the life of the patient. In case of massive hemorrhage, performing hysterectomy may be a lifesaving intervention to the patient.^{17,19} It is also advisable in older patient especially ≥ 40 years old women whose risk of developing GTN is increased.¹⁵ Because malignant

sequelae are mostly occur in older age groups after molar evacuation (37.5% of patients aged ≥ 50 years; 27.5% of patients aged 40–49 years; 13.9% of patients aged ≤ 15 years).⁶ Hysterectomy plays an important role in the management of older patients and lowers risk for malignant sequelae than with suction curettage. Hysterectomy decreases the risk for postmolar GTN to 3.5% compared to 20% risk following suction curettage.⁶ However, this procedure does not eliminate the possibility of the metastasis to the other organs in case of GTN.^{18,19} Bahar et al concluded that primary hysterectomy does not worsen the prognosis of GTD and it does not eliminate the need for follow-up.²¹ The patients still require follow-up with assessment of hCG levels. A careful β -

hCG level monitoring is important to detect persistence of trophoblastic disease as a specific marker secreted by trophoblast cell.⁵ The measurement can be perform at 48 hours after molar evacuation, then the results were compared with another examination every 1 to 2 weeks until the β -hCG levels cannot be detected anymore, followed by examination every month for 6 consecutive months. Once the levels of β -hCG result is confirmed to be in normal level, the patient is allowed to get pregnant.^{7,15} Pregnancy during this monitoring can be a complicating factor in the interpretation of β -hCG levels. Therefore, patient should be recommend to use contraception (hormonal or barrier).¹⁴

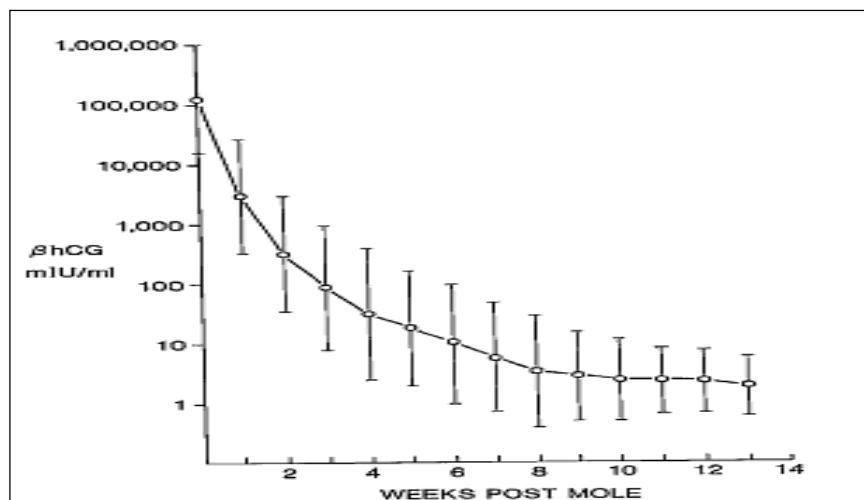


Figure 3. Post Molar Pregnancy regression curve of serum β -hCG⁹

Approximately 50% of gestational trophoblast neoplasm arise from hydatidiform mole. About 15-20% of complete hydatidiform mole cases develops into gestational trophoblastic neoplasms (GTN). Whereas partial hydatidiform moles have

a risk of 1-5% to develop into GTN. Risk factors for neoplasm includes β -hCG levels $> 100,000$ mIU/mL, uterine size larger than gestational age; theca-lutein cysts > 6 cm, and older age (≥ 40 years old).^{7,14}

Table 1. Diagnostic Criteria for Gestational Trophoblastic Neoplasm⁷

- | |
|--|
| <ol style="list-style-type: none"> 1. Plateau of serum β-hCG for 4 measurements during a period of 3 weeks or longer (day 1, 7, 14, 21) 2. Rise of serum β-hCG level $> 10\%$ during 3 weekly consecutive measurements or longer, during a period of 2 weeks or more (day 1, 7, 14) 3. Serum β-hCG level remains detectable for 6 months or more 4. Histological criteria for choriocarcinoma |
|--|

The treatment for this patient was decided based on some considerations, such as her age (48 years old which increase her risk of malignancy) and her completion of childbearing (hysterectomy considered as surgical sterilization, because she already has two children). The monitoring follow up of β -hCG levels also can be challenging, because it

was cost and time consuming process, especially in developing country where the decision making were influenced by some factors. The contributing factors due to poor follow up in developing countries are low socio-economic status, geographical problems (patient came from remote area with a lack of proper facilities to reach the hospital), and poor

literacy level (patient's inability to understand the importance of follow up).²² These acknowledgements lead us to do hysterectomy because it can reduce the risk of malignancy higher than suction curettage. Therefore, we decided to do a laparotomy total abdominal hysterectomy with an incidental finding of mass at fundal of the uterine, which suspected as invasive mole.

Conclusion

Hydatidiform mole is a rare but important pregnancy related condition which can develop into gestational trophoblast neoplasm. An early diagnosis is needed to determine the management plan. The primary management is surgical evacuation followed by β -hCG levels monitoring. Although suction curettage is the

most frequent technique for molar evacuation, hysterectomy is a reasonable option as primary treatment to be performed in older patients and for those who do not wish to preserve their fertility. The other important points such as socio-economic status, education level, and geographical issues should be considered also on managing older patients with hydatidiform mole in developing countries.

Acknowledgement

-

Conflict of interest

None

References

1. Almeida CE, Curi EF, Almeida CR, Vieira DF. Thyrotoxic Crisis Associated with Gestational Trophoblastic Disease. *Revista Brasileira de Anestesiologia*. 2011; 61: 5: 604-9.
2. Lurain JR. Gestational Trophoblastic Disease I: Epidemiology, Pathology, Clinical Presentation and Diagnosis of Gestational Trophoblastic Disease, and Management of Hydatidiform Mole. *American Journal of Obstetrics & Gynecology*. 2010.
3. Women and Newborn Health Service King Edward Memorial Hospital. Abnormalities of Early Pregnancy. Government of Western Australia. 2015.
4. Union for International Cancer Control. Gestational Trophoblastic Neoplasia : Review of Cancer Medicines on the WHO List of Essential Medicines. 2014
5. Niemann I, Vejerslev LO, Frøding L, Blaaekær J, Maroun LL, Hansen ES, et al. Gestational Trophoblastic Diseases Clinical Guidelines for Diagnosis, Treatment, Follow-up, and Counseling. *Dan Med J*. 2015;62(11): 1-19.
6. Hanna RK, Soper JT. The Role of Surgery and Radiation Therapy in the Management of Gestational Trophoblastic Disease. *The Oncologist*. 2010;15:593–600.
7. Cunningham FG, Leveno KJ, Bloom SL, Spong CY, Dashe JS, Hoffman BL, etc. *Williams Obstetrics*. McGraw Hill. 24th ed. Pg 396- 404.
8. Prawirohardjo S. *Ilmu Kebidanan*. Jakarta: Bina Pustaka Sarwono Prawirohardjo; 2009. p. 489.
9. Berkowitz RS, Goldstein DP, Horowitz NS. Hydatidiform mole: Management. *Uptodate*. 2014.
10. Seckl M.J, Sebire N.J, Fisher R.A, Golfier F, Massuger L, Sessa C. Gestational Trophoblastic Disease : ESMO Clinical Practice Guidelines for Diagnosis, Treatment, and Follow-up. *Annals of Oncology*. 2013: 1-12.
11. Zhou Q, Lei XY, Xie Q, Cardoza JD. Sonographic and doppler imaging in the diagnosis and treatment of gestational trophoblastic disease: a 12-year experience. *J Ultrasound Med*. 2005; 24: 15-24.
12. Nair K, Al-Khawari H. Invasive Mole of the Uterus – A Rare Case Diagnosed by Ultrasound: A Case Report. *Med Ultrason*. 2014;16(2): 175-178.

13. Deep JP, Sedhai LB, Napit J, Pariyar J. Gestational Trophoblastic Disease. *Journal of Chitwan Medical College*. 2013; 3(4): 4-11.
14. Walkington L, Webster J, Hancock BW, Everard J, Coleman RE. Hyperthyroidism and human chorionic gonadotrophin production in gestational trophoblastic disease. *British Journal of Cancer*. 2011; 1665 – 69.
15. Cavaliere A, Ermito S, Dinatale A, Pedata R. Management of Molar Pregnancy. *Journal of Prenatal Medicine*. 2009; 3(1): 15-17.
16. Gerulath AH. SOGC Clinical Practice Guidelines: Gestational Trophoblastic Disease. *JOGC*. 2002; 1-6.
17. Sinan S, Oge T. Surgical Management in Gestational Trophoblastic Disease. *Journal of Turkish Society of Obstetrics and Gynecology*. 2012; 9: 133-41.
18. New Zealand Gynaecology Cancer Group Guidelines : Gestational Trophoblastic Disease. *NZGTD*. 2014; 1-13.
19. Daftary SN, Chakravarti S, Kusthagi P. *Manual of Obstetrics*. 3rd ed. India: Elsevier Health Sciences. 2015; 241.
20. Berek JS. *Berek & Novacks*. 14th ed. USA: Lippincot Williams & Wilkins; 2007; 1581-1601.
21. Bahar AM, el-Ashnehi MS, Senthilselvan A. Hydatidiform mole in the elderly: hysterectomy or evacuation?. *Int J Gynaecol Obstet*. 1989;29 (3): p. 233-8.
22. Aziz N, Yousfani S, Soomro I, Mumtaz F. Gestational Trophoblastic Disease. *J Ayub Med Coll Abbottabad*. 2012; 24: 7-9.